

CASE REPORT

Open Access



Testicular metastasis as the first clinical manifestation of pancreatic adenocarcinoma: a case report

Luigi Cormio^{1*}, Francesca Sanguedolce², Paolo Massenio¹, Giuseppe Di Fino¹, Mariantonietta Bruno³ and Giuseppe Carrieri¹

Abstract

Introduction: Testicular metastases from pancreatic carcinomas are extremely rare and are usually seen in the late phase of the disease. Fewer than 10 cases have been reported in the literature to date, all of which occurred in patients more than 50 years old. Herein we describe the first case, to our knowledge, of testicular metastasis as the first clinical manifestation of pancreatic carcinoma in a young adult.

Case presentation: A 36-year-old Caucasian man presented to our institution with an acutely developed severe pain in his right testis. His clinical examination and scrotal ultrasounds were consistent with a tumor involving the entire right testis. The patient underwent radical orchiectomy. His pathologic examination revealed the tumor to be a metastasis from a pancreatic cancer that was confirmed by an abdominal computed tomographic scan.

Conclusions: The present case shows that testicular metastasis could be the presenting sign of metastatic pancreatic cancer and that testicular metastases from solid organ tumors, though typical of elderly people, may occasionally be seen in young adults as well.

Keywords: Immunohistochemistry, Pancreatic cancer, Testicular metastasis

Introduction

Testicular metastases from solid non-lymphoid tumors are extremely rare, accounting for only 0.02% to 3.6% of all testicular neoplastic lesions [1–3]. They usually affect males over 50 to 60 years of age, and it is extremely uncommon for them to present as the first clinical manifestation of the underlying malignancy [4, 5]. Primary sites include, in a roughly descending order, the prostate, lung, skin (melanoma), kidney, digestive tract, and adrenal gland (neuroblastoma). Testicular metastases from the bladder, soft tissue, and penis have been described occasionally [6–8].

In a review of the literature, we found fewer than 10 cases of testicular metastases arising from a pancreatic neoplasm, all of which occurred in patients more than 50 years old [4–7]. Herein we describe the first case, to

our knowledge, of testicular metastasis as the first clinical manifestation of pancreatic carcinoma in a young adult.

Case presentation

A 36-year-old Caucasian man presented to our institution with an acutely developed severe pain in his right testis. One year before this presentation, owing to azoospermia, he had undergone bilateral testicular biopsy and sperm retrieval that led to pregnancy. Clinical examination disclosed bilateral hypogonadism with a hard and nodular right testis and absence of palpable inguinal and pelvic nodes. Scrotal ultrasounds showed marked structural changes of the entire right testis (Fig. 1). A pre-operative chest X-ray and blood tests, including the β -subunit of human chorionic gonadotropin (β -hCG) and α -fetoprotein (AFP), were all normal. The patient underwent right radical orchiectomy. His pathologic examination revealed infiltration of the testis by a poorly differentiated carcinoma with mucinous and micropapillary features (Fig. 2). The cancer-free testicular tissue

* Correspondence: luigicormio@libero.it

¹Department of Urology and Renal Transplantation, University of Foggia, Foggia, Italy

Full list of author information is available at the end of the article

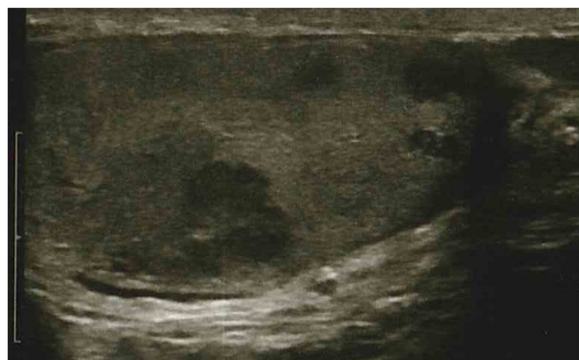

Fig. 1 Scrotal ultrasound. Structural changes of the entire right testis

showed mostly regular tubules with normal spermatogenesis, despite the macroscopic findings. Careful examination of the entire lesion allowed us to rule out teratoma. Immunohistochemically, the tumor was positive for cytokeratin (CK) 7 and CK20 (focal) and negative for placental alkaline phosphatase (PLAP), AFP, β -hCG, calretinin, and inhibin, with a Ki67/MIB1 proliferation index of 15%.

Taken together, such findings allowed us to rule out a primitive testicular cancer as well as metastasis from hepatocellular carcinoma, and they were consistent with metastatic adenocarcinoma of the pancreas. Chest and abdominal computed tomography demonstrated the presence of a tumor of the tail of the pancreas (Fig. 3), along with hepatic metastases. There was no evidence of retroperitoneal lymphadenopathy. Serum tumor markers such as cancer antigen (CA) 125 and CA 19-9 levels were within normal range. The patient was given chemotherapy but died 3 months later.

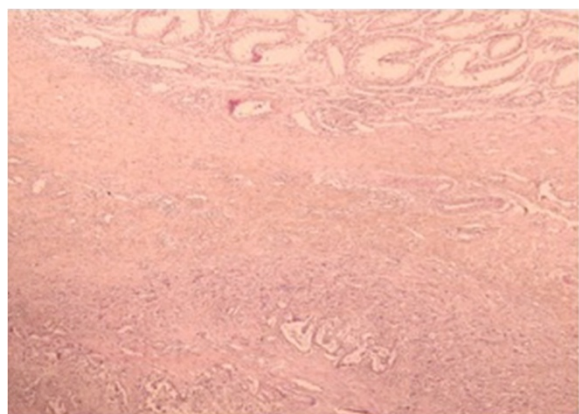


Fig. 2 Histologic examination revealed a metastatic adenocarcinoma to the testis with residual seminiferous tubules (top). Hematoxylin and eosin stain; original magnification, 400 \times

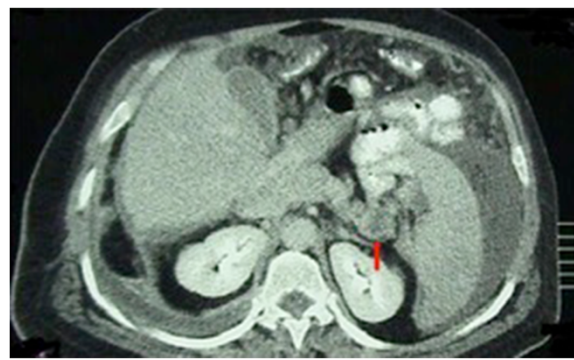

Fig. 3 Computed tomographic scan. Densitometric alteration of the tail of the pancreas can be seen (inhomogeneous hypodensity, red arrow)

Discussion

The low incidence of secondary tumors to the testis is apparently due to the lower temperature of the scrotum, which could impair the metastatic ability of tumor cells from solid organs [7, 9].

Various routes of spread of metastatic tumors to the testes have been suggested, including arterial embolization, retrograde venous spread, retrograde lymphatic spread, direct spread along the vas deferens to the epididymis, and transperitoneal seeding through a patent tunica vaginalis. The dissemination mechanism seems to vary with type and location and the primary tumor, and one does not exclude the other [3, 10]. In general, for primary tumors that are located outside the pelvic and abdominal cavity, arterial dissemination seems to be the preferred route [11]. Given the absence of retroperitoneal lymphadenopathy, this was likely the case in our patient. Transperitoneal seeding is probable when peritoneal carcinomatosis is present [12].

Testicular metastases usually are a final manifestation of widely disseminated tumors, and therefore they often go unnoticed [6]. Rarely, they represent the first clinical manifestation of the underlying malignancy [4, 5], thus simulating a primary testicular tumor, as in our patient.

Clinically, there are no specific features that differentiate primary from secondary testicular tumors, as both may present with local pain, tenderness, nodular lesions, or an indurated testis; painless swelling, however, points toward the diagnosis of a testicular tumor. Also, serum tumor markers such as AFP and β -hCG are not helpful in distinguishing primary from secondary testicular tumors. On the one hand, normal values may be consistent with primary as well as secondary malignancies; on the other hand, elevated values may be related to gonadal as well as extragonadal tumors [5]. Interestingly, one of the few reported cases of pancreatic adenocarcinoma presenting as a testicular tumor featured raised hCG levels due to extragonadal secretion [13]. However, that patient

was 77 years old, thus suggesting the testicular tumor to be a secondary rather than a primary malignancy. As a matter of fact, the patient's age may play an important role in differentiating a primary tumor from a secondary one. Patients with testicular metastases are older than those with primary testicular tumors [14–16], as the peak incidence of testicular metastases from all tumors is in the sixth decade of life, according to several large series reported in literature. Therefore, the peculiarity of our patient is that he was a young adult with bilateral hypogonadism and azoospermia, features that pointed toward the diagnosis of a primary testicular tumor. Pathologic examination is essential to differentiating primary from secondary testicular tumors. The first important feature is the absence of intratubular malignant germ cell neoplasms [16]. In the large series reported by García-González *et al.* [6], two architectural patterns were identified: an interstitial one, which can also be seen in primary tumors, though less frequently, and a destructive one, which was present in our patient. According to Price and Mostofi [14], another feature that increases the possibility of metastatic rather than primary tumor is the presence of tumor emboli in the vascular channels of the parenchyma and tunica albuginea, though intravascular invasion was very rarely found in another small series [6]. In our patient, no lymphovascular invasion was detectable in the testis.

Immunohistochemistry is nowadays regarded as the most sensitive and specific way of determining the origin of the tumor. Recently, new markers have been developed and are being used in diagnosis. These include homeobox protein NANOG, SOX2, and Oct-3/4 [17, 18]. In our patient, the histological diagnosis relied on positive immunohistochemical staining for CK7, CK20 (focal), and negative staining for PLAP, AFP, β -hCG, calretinin, inhibin, and a Ki67/MIB1 proliferation index of 15%, findings that were altogether consistent with metastatic adenocarcinoma of the pancreas. Serum CA 125 and CA 19-9 levels were within normal range, but abdominal computed tomography revealed the pancreatic tumor along with the hepatic metastases.

Conclusions

The present case shows that testicular metastasis can be the presenting sign of metastatic pancreatic cancer and that testicular metastases from solid organ tumors, though typical of elderly people, may occasionally be seen in young adults as well.

Consent

Written informed consent was obtained from the patient's next of kin for publication of this case report and any accompanying images. A copy of the written consent is available for review by the Editor-in-Chief of this journal.

Abbreviations

AFP: α -Fetoprotein; β -hCG: β -Subunit of human chorionic gonadotropin; CA: Cancer antigen; CK: Cytokeratin; PLAP: Placental alkaline phosphatase.

Competing interests

The authors declare that they have no competing interests.

Authors' contributions

LC: manuscript conception and critical revision. FS and PM: manuscript drafting. GDF: data acquisition. MB: pathology review. GC: supervision. All authors read and approved the final manuscript.

Author details

¹Department of Urology and Renal Transplantation, University of Foggia, Foggia, Italy. ²Department of Pathology, University of Foggia, Foggia, Italy. ³Department of Pathology, Madonna delle Grazie Hospital, Matera, Italy.

Received: 19 January 2015 Accepted: 25 May 2015

Published online: 12 June 2015

References

- Grignon DJ, Shum DT, Hayman WP. Metastatic tumours of the testes. *Can J Surg*. 1986;29:359–61.
- Gomes CA, Soares Jr C, de Assis EACP, de Souza Silva TA, Stroppa Faquin CM, de Paula VL, et al. Metastatic and synchronous melanoma in the testicle and paratesticular region. *J Clin Exp Dermatol Res*. 2012;3:139. doi:10.4172/2155-9554.1000139.
- Dutt N, Bates AW, Baithun SI. Secondary neoplasms of the male genital tract with different patterns of involvement in adults and children. *Histopathology*. 2000;37:323–31.
- Rosales Bordes A, Montlleó González M, Villavicencio Mavrich H, Algaba Arrea F. [Metastatic testicular carcinoma]. *Arch Esp Urol*. 2000;53(6):469–71. Spanish.
- Haupt HM, Mann RB, Trump DL, Abeloff MD. Metastatic carcinoma involving the testis: clinical and pathologic distinction from primary testicular neoplasms. *Cancer*. 1984;54:709–14.
- García-González R, Pinto J, Val-Bernal JF. Testicular metastases from solid tumors: an autopsy study. *Ann Diagn Pathol*. 2000;4:59–64.
- Ulbricht TM, Young RH. Metastatic carcinoma to the testis: a clinicopathological analysis of 26 nonincidental cases with emphasis on deceptive features. *Am J Surg Pathol*. 2008;32:1683–93.
- Lioe TF, Biggart JD. Tumours of the spermatic chord and paratesticular tissue: a clinicopathological study. *Br J Urol*. 1993;71:600–6.
- Tiltman AJ. Metastatic tumours in the testis. *Histopathology*. 1979;3:31–7.
- Meacham RB, Mata JA, Espada R, Wheeler TM, Schum CW, Scardino PT. Testicular metastasis as the first manifestation of colon carcinoma. *J Urol*. 1988;140(3):621–2.
- Richardson PG, Millward MJ, Shrimankar JJ, Cantwell BM. Metastatic melanoma to the testis simulating primary seminoma. *Br J Urol*. 1992;69:663–5.
- Yang KC, Chao Y, Luo JC, Kuo JY, Lee RC, Li AFY, et al. The unusual presentation of gastric adenocarcinoma as a testicular mass: a favorable response to docetaxel and cisplatin plus oral tegafur/uracil and leucovorin. *J Chin Med Assoc*. 2010;73:88–92.
- Taylor H, Heaton N, Farrands P, Kirkham N, Fletcher M. Elevated human chorionic gonadotrophin levels in a patient with pancreatic carcinoma presenting with a testicular metastasis. *Postgrad Med J*. 1990;66:1073–5.
- Price Jr EB, Mostofi FK. Secondary carcinoma of the testis. *Cancer*. 1957;10:592–5.
- Almagro UA. Metastatic tumors involving testis. *Urology*. 1988;32:357–60.
- Sharma MC, Sudha K, Singh MK, Chahal R, Sood R. Metastatic tumors involving the testes. *Indian J Pathol Microbiol*. 1996;39(4):293–6.
- Iczkowski KA, Butler SL, Shanks JH, Hossain D, Schall A, Meiers I, et al. Trials of new germ cell immunohistochemical stains in 93 extragonadal and metastatic germ cell tumors. *Hum Pathol*. 2008;39:275–81. A published erratum appears in *Hum Pathol*. 2013;44(12):2873.
- Sonne SB, Perrett RM, Nielsen JE, Baxter MA, Kristensen DM, Leffers H, et al. Analysis of SOX2 expression in developing human testis and germ cell neoplasia. *Int J Dev Biol*. 2010;54:755–60.