

Case report

Open Access

Pulmonary manifestations in a pediatric patient with ulcerative colitis: a case report

Ryan S Carvalho, Lindsay Wilson and Carmen Cuffari*

Address: The Johns Hopkins University School of Medicine, Department of Pediatrics, Division of Pediatric Gastroenterology and Nutrition, Baltimore, Maryland, USA

Email: Ryan S Carvalho - rcarval2@jhmi.edu; Lindsay Wilson - lwilson@jhmi.edu; Carmen Cuffari* - ccuffari@jhmi.edu

* Corresponding author

Published: 25 February 2008

Received: 11 September 2007

Journal of Medical Case Reports 2008, **2**:59 doi:10.1186/1752-1947-2-59

Accepted: 25 February 2008

This article is available from: <http://www.jmedicalcasereports.com/content/2/1/59>

© 2008 Carvalho et al; licensee BioMed Central Ltd.

This is an Open Access article distributed under the terms of the Creative Commons Attribution License (<http://creativecommons.org/licenses/by/2.0>), which permits unrestricted use, distribution, and reproduction in any medium, provided the original work is properly cited.

Abstract

Introduction: Although respiratory involvement has been described in patients with IBD, well-defined interstitial lung disease has not been reported, especially among children with ulcerative colitis.

Case presentation: Herein, we present a case of an adolescent female with ulcerative colitis and extra-intestinal complications involving the lungs that were effectively treated with anti-metabolite therapy.

Conclusion: Children with UC may manifest either interstitial or large airway pulmonary involvement. All children with suspected lung involvement should be screened for tuberculosis prior to starting immunosuppressive therapy.

Introduction

The most prevalent pulmonary manifestation in either Crohn's disease (CD) or ulcerative colitis (UC) is non-specific airway inflammation [1-3]. Untreated, patients are at risk for developing bronchiolitis obliterans with organizing pneumonia, tracheal stenosis and bronchiectasis [4,5]. Although necrobiotic lung nodules are less common, they represent an important pulmonary manifestation of interstitial lung disease in patients with IBD [6]. In Pediatrics, the pulmonary manifestations of IBD have been recognized only in children with CD [7-9]. Herein, we describe a pediatric patient with ulcerative colitis and pulmonary manifestations that were effectively treated with immunosuppressive therapy.

Case presentation

A 13.5 yr. old female with UC diagnosed a year prior, presented at a local hospital emergency room with a 1 month

history of abdominal pain and diarrhea that progressed to frank hematochezia. Her symptoms were also associated with fever, night sweats, malaise, decreased appetite and weight loss. A chest and abdominal computerized tomography (CT) scan showed a 4 cm nodule in the lingula (Fig. 1a) and 2 smaller nodules in the left lower lobe. A CT-guided biopsy of the lingular mass showed no malignancy, but marked alveolar inflammation. The patient was also PPD negative, and all cultures, including blood, sputum and lung tissue for bacteria, atypical mycobacteria, virus and fungal organisms were negative.

The patient was transferred to The Johns Hopkins's Children's Center for further evaluation. Pulmonary functions testing showed mild obstructive, but no restrictive lung disease. A transbronchial biopsy of the lingular mass verified the presence of a necrobiotic nodule, and repeat tissue cultures were also negative. The patient continued to

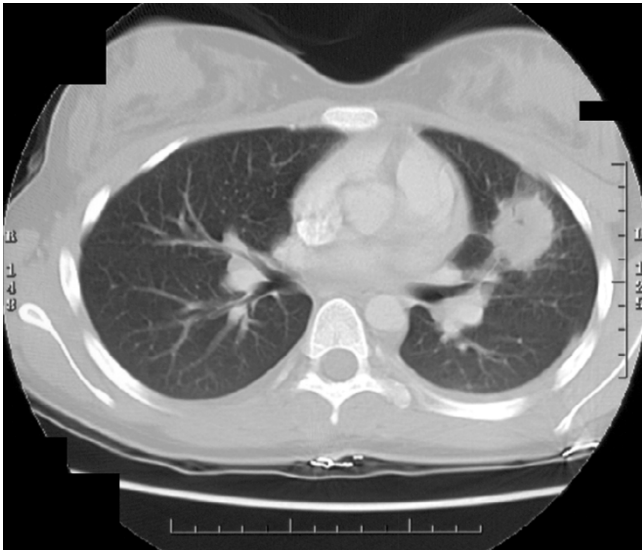


Figure 1
Chest CT scan showing a well-circumscribed homogeneous pulmonary mass (4 cm) within the lingular of the left lung in a newly diagnosed child with ulcerative colitis.

have frequent bloody diarrhea that was treated with intravenous corticosteroids, parenteral nutrition, antibiotics and mesalamine therapy. The patient's symptoms resolved within 5 days of initiating therapy. She was prescribed 6-mercaptopurine (1 mg/Kg/day) upon discharge from hospital, and has remained essentially asymptomatic up to 3 years in follow-up. A repeat chest CT done at 12 months post discharge showed complete resolution of the 2 small left lower lobe lesions, however, the lingular lesion was replaced with a residual thin-walled cyst measuring 2.4 × 3.4 cm in diameter (Fig. 1b).

Discussion

Although extra intestinal manifestations are relatively common (13–45%) in patients with IBD [2], pulmonary manifestations are considered rare [1-3]. Moreover, while there have been reported cases of pulmonary manifestations in pediatric CD [7-9], this is the first reported case of interstitial lung involvement in a child with UC. In comparison, Camus and coworkers have described a number of pulmonary manifestations in adult patients with UC, including bronchiolitis obliterans with organizing pneumonia, chronic bronchitis, bronchiectasis, bronchiolitis, serositis and interstitial lung disease. Most (> 60%) of the patients manifested pulmonary symptoms during periods of quiescent bowel disease, and there was no correlation between age at bowel disease onset, and either the time of onset of respiratory symptoms or the degree of respiratory involvement. Although 8 patients were diagnosed with UC in childhood, all developed respiratory symptoms

during adulthood. Moreover, proctocolectomy was not shown to be protective against a recurrence of pulmonary symptoms [1].

In a study by Songur and coworkers, 66% of patients with respiratory symptoms had abnormal pulmonary function tests (PFTs) [10]. More importantly, abnormal PFT's (> 80%), including a reduction in expiratory flow were detected during periods of increased bowel disease activity, as was also noted in pediatric case. In an Eastern European case series, 56% of patients with UC showed a decrease in lung diffusion capacity with no radiographic change. In that study, just 16.7% of these patients were smokers [11]. Although these studies would support the use of PFTs in diagnosing pulmonary disease and following clinical responsiveness to therapy in patients with IBD, the role of routine pulmonary testing has yet to be determined [12]. Longitudinal epidemiological studies may help define the true prevalence of pulmonary disease in children with UC and identify whether risk factors, including family history, smoking, and serological biomarkers can predict this disease phenotype.

Conclusion

Children with UC may manifest either interstitial or large airway pulmonary involvement. Albeit rare, patients may present with life threatening complications of respiratory disease. Our patient responded to systemic corticosteroid and maintenance anti-metabolite therapy. While there is no epidemiologic pediatric data on the incidence of either infectious or inflammatory pulmonary complications in children with UC, an infectious etiology would still need to be excluded in all patients prior to implementing immuno-modulatory therapy, as was done in our case series. Moreover, all children should be screened for tuberculosis through skin testing, especially now with the increased use of biological therapies.

Abbreviations

Ulcerative Colitis, UC; Crohn's disease, CD; Interstitial lung disease, ILD; Pulmonary function test, (PFT); Computerized tomography, CT; Erythrocyte sedimentation rate, ESR.

Competing interests

The author(s) declare that they have no competing interests.

Authors' contributions

All the authors contributed equally in the patient summary, research, referencing, review, writing and proof-reading of the case report.

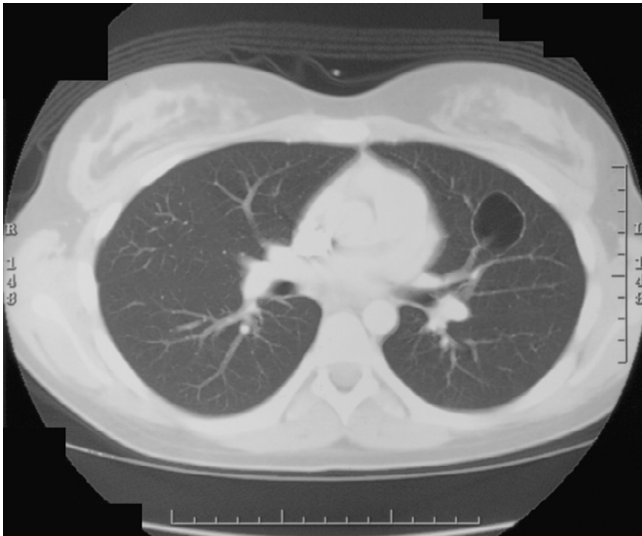


Figure 2
Follow-up (12 mo.) chest CT scan in the same patient on maintenance 6-mercaptopurine therapy with a residual cavitary lesion within the lingular of the left lung.

Consent

The patient's family had a chance to review the manuscript and provide verbal consent for its submission for publication.

References

1. Camus P, Piard F, Ashcroft T, Gal AA, Colby TV: **The lung in inflammatory bowel disease.** *Year Book of digestive diseases Medicine* 1994, **72(3)**:151-183.
2. Greenstein AJ, Janowitz HD, Sachar DB: **The extraintestinal complications of Crohns disease and Ulcerative Colitis.** *Medicine* 1976, **55**:401-412.
3. Rankin GB, Watts HD, Melnyk CJ: **National Cooperative Crohn's disease study: Extraintestinal manifestations and perianal complications.** *Gastroenterology* 1979, **77(4)**:914-920.
4. Kinnear W, Higenbottam T: **Pulmonary manifestations of IBD.** *Int Med Spec* 1983, **4**:104-111.
5. Desai SJ, Gephardt GN, Stoller JK: **Diffuse panbronchiolitis preceding ulcerative colitis.** *Chest* 1989, **95(6)**:1342-1344.
6. Casey MB, Tazelaar HD, Myers JL, Hunninghake GW, Kalra SX, Ashton R, Colby TV: **Non infectious lung pathology in patients with Crohn's disease.** *Am J Surg Path* 2003, **27**:213-219.
7. Fan LL, Mullen AL, Brugman SM, Inscore SC, Parks DP, White CW: **Clinical spectrum of chronic interstitial lung disease in children.** *J Pediatr* 1992, **121**:867-72.
8. Calder CJ, Lacy D, Raafat F, Weller PH, Booth IW: **Crohn's disease with pulmonary involvement in a 3 year old boy.** *Gut* 1993, **34**:1636-8.
9. Puntis JW, Tarlow MJ, Raafat F, Booth IW: **Crohn's disease of the lung.** *Arch Dis Child* 1990, **65**:1270-1271.
10. Songur N, Songur Y, Tuzun T, Dogan I, Tuzun D, Hekimoglu B: **Pulmonary function tests and High resolution CT in the detection of Pulmonary involvement in Inflammatory bowel disease.** *J Clin Gastroenterol* 2003, **37**:
11. Kuzela L, Vavrecka A, Prikazska M, Drugda B, Hronec J: **Pulmonary complications in patients with inflammatory bowel disease.** *Hepatogastroenterology* 1999, **46**:1714-1719.
12. Eade OE, Smith CCL, Alexander JR, Whorehell PJ: **Pulmonary function in patients with inflammatory bowel disease.** *Am J Gastro* **180(73)**:154-156.

Publish with **BioMed Central** and every scientist can read your work free of charge

"BioMed Central will be the most significant development for disseminating the results of biomedical research in our lifetime."

Sir Paul Nurse, Cancer Research UK

Your research papers will be:

- available free of charge to the entire biomedical community
- peer reviewed and published immediately upon acceptance
- cited in PubMed and archived on PubMed Central
- yours — you keep the copyright

Submit your manuscript here:
http://www.biomedcentral.com/info/publishing_adv.asp

