

CASE REPORT

Open Access



Concomitant spontaneous subdural and intracystic hematoma in arachnoid cyst: a case report and review of the literature

Mohamed K. Elkazaz^{1*}  and Khaled El-Sayed¹

Abstract

Background Intracystic hematoma in arachnoid cyst are a very rare pathology that commonly occurs after head trauma, while spontaneous intracystic hematomas in arachnoid cyst associated with subdural hematoma is extremely rare. Currently there are 33 patients of spontaneous intracystic hematomas in arachnoid cyst reported in the literature. In this case report we present an adult patient with concomitant chronic subdural hematoma with intracystic hematoma in arachnoid cyst.

Case presentation A 19-year-old Egyptian Arabian female patient presented to the outpatient clinic complaining of severe headache of 1-month duration that was progressive in nature. Provisionally, it was thought that it might be an arachnoid cyst with associated chronic subdural hematoma along with intracystic hematoma. Decision to proceed with craniotomy and cyst evacuation was made.

Conclusion Concomitant intracystic hematoma in arachnoid cyst along with subdural hematoma is a serious condition that might be life-threatening if not well managed.

Keywords Arachnoid, Cyst, Hematoma, Subdural

Background

Arachnoid cysts (AC), either congenital or acquired, are mainly filled with cerebrospinal fluid (CSF) and lined by meningotheial cells with epithelial membrane antigen (EMA). They are thought to be derived from splitting of arachnoid membrane. Commonly, they mainly do not communicate neither with subarachnoid space nor the ventricular system [1–3].

AC occur in different sites inside the brain, and 50% occur in the sylvian fissure. The cerebellopontine angle is the second most common site. It is usually asymptomatic and accidentally discovered in brain imaging.

However, some patients may develop symptoms such as seizures, decreased milestones, projectile vomiting, and/or impaired cognition [4, 5].

AC account for approximately 1% of cranial space-occupying lesions [6, 7]. Intracystic hematoma in AC is a very rare pathology that commonly occurs after head trauma. Spontaneous intracystic hematoma in AC associated with subdural hematoma (SDH) is extremely rare [6, 8, 9]. Currently there are 33 cases reported in the literature of patients with concomitant spontaneous intracystic hematoma in AC and SDH. In this case report we present an adult patient with concomitant chronic SDH with intracystic hematoma in AC.

Case presentation

A 19-year-old Egyptian Arabian female patient presented to the outpatient clinic complaining of a severe headache of 1-month duration that was progressive in nature. The

*Correspondence:

Mohamed K. Elkazaz

Mohamed.elkazaz@med.suez.edu.eg

¹ Neurosurgery Department, Faculty of Medicine, Suez Canal University Teaching Hospital, Suez Canal University, Ismailia, Egypt



headache worsened when she leaned forward, coughed, or strained. She did not complain of vomiting or nausea, however, she mentioned that she had an attack of a sudden loss of consciousness 1 week ago that was described by her family members as generalized tonic–clonic seizures. She denied any history of head trauma, chronic illnesses, or use of medications such as blood thinners or anticoagulants. On examination, she was fully conscious and oriented to time, place, and person, with no apparent craniopathies or sensory deficit, however, she had positive pronator drift sign on her right upper limb with no alteration in her gait. Her brain computed tomography (CT) showed left fronto-temporo-parietal isodense lesion associated with contralateral subfalcine herniation around 12 mm along with ipsilateral ventricular effacement and contralateral temporal horn dilatation (Fig. 1). Brain magnetic resonance imaging (MRI) showed on T1w images (Fig. 1) a left hyperintense fronto-temporo-parietal lesion with two different hyperintensities in the temporal region. Furthermore, T2w images of the brain

MRI (Fig. 1) revealed two distinct left temporal intensities, one a medial hypointense crescent-shaped lesion and the other hyperintense and extending to the left fronto-parietal. After requiring proper consent for management and inclusion in the department research database, the patient was admitted to the neurosurgery ward and blood investigations were carried out; all of them came back unremarkable for any pathologies such as coagulopathy or anemia. Provisionally, it was thought it might be an AC with associated chronic subdural hematoma along with intracystic hematoma. Decision to proceed with craniotomy and cyst evacuation was made. The patient was put under general anesthesia in supine position with contralateral head tilt and ipsilateral shoulder roll, and after craniotomy and durotomy, chronic blood pooled from the subdural space (Fig. 2), and the appearance of the AC membrane with a visible puncture in it was observed (Fig. 2). Saline irrigation inside continued until fluid came out clear. Standard closure of the dura and the skin was done with a subdural non-suction drain

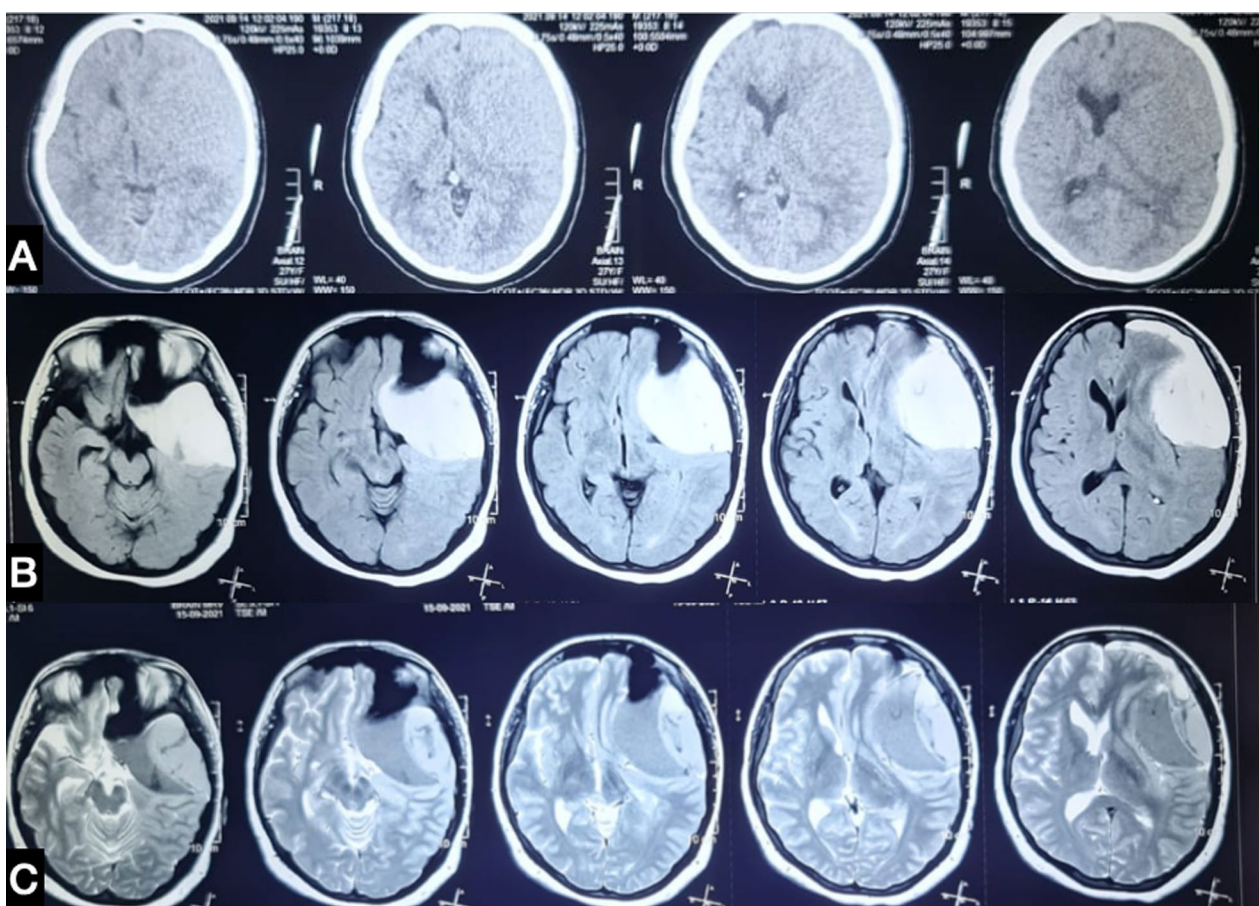


Fig. 1 Preoperative. **A** CT brain axial section shows subfalcine herniation with an isodense lesion in left fronto-temporo-parietal region. **B** T1w axial sections shows hyperintense lesion filling the left temporal fossa and extending frontal and parietal. **C** T2w axial sections shows multiple intensity lesions with a clear margin between them; medial is hypointense and lateral is hyperintense

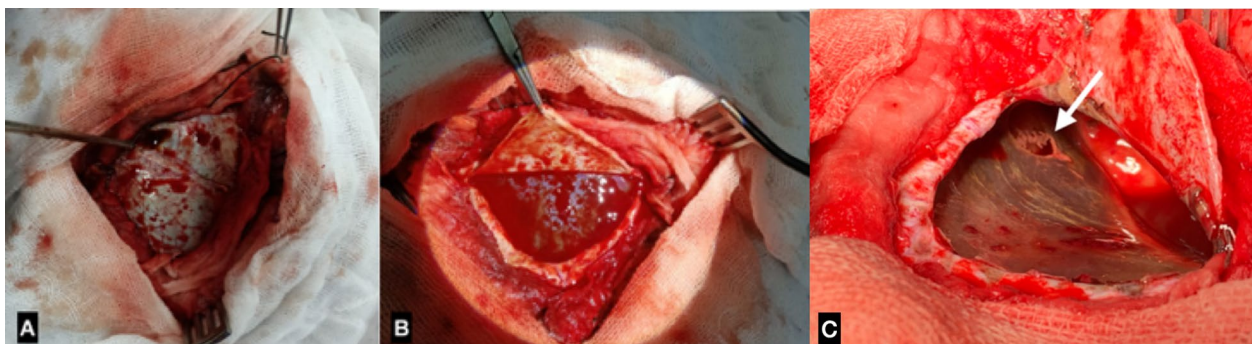


Fig. 2 Operative images. **A** Dura is bluish and congested. **B** After durotomy subdural hematoma is found covered by a membrane. **C** The white arrow shows the defect found in the arachnoid cyst membrane

left inside. On the same day patient recovered from the anesthesia fully conscious, she admitted that the headache was relieved, and she was neurologically intact. Brain CT was done on the next day (Fig. 3) and showed full expansion of the AC with recovery of midline shift. Drain on the next day was filled with CSF tinged with blood. The drain was left for 4 days following the surgery and drain site in the skin was stitched. Patient was discharged from the hospital on day 5, and 1 month later brain MRI was done (Fig. 4) and showed AC with hypointensity on T1w and hyperintensity on T2w. The patient was clinical and neurologically better. No complications were encountered during the operation or postoperative periods.

Discussion

The vast utilization of radiological imaging of the nervous system has raised the accidental discovery of AC. The utmost is revealed throughout the first two decades. AC forms around 1% of all intracranial space-occupying lesions [1]. Common sites include the middle cranial fossa, peri-sellar, retro-cerebellar, cerebral convexity, quadrigeminal plate cisterns, and cerebellopontine angle [10].

Most AC are congenitally formed, however, some AC result from a postinflammatory state after infection or trauma. Congenitally formed AC are thought to form due to derangement during arachnoid development, resulting in splitting of the arachnoid membrane with a space filled with CSF, mainly a mesenchymal

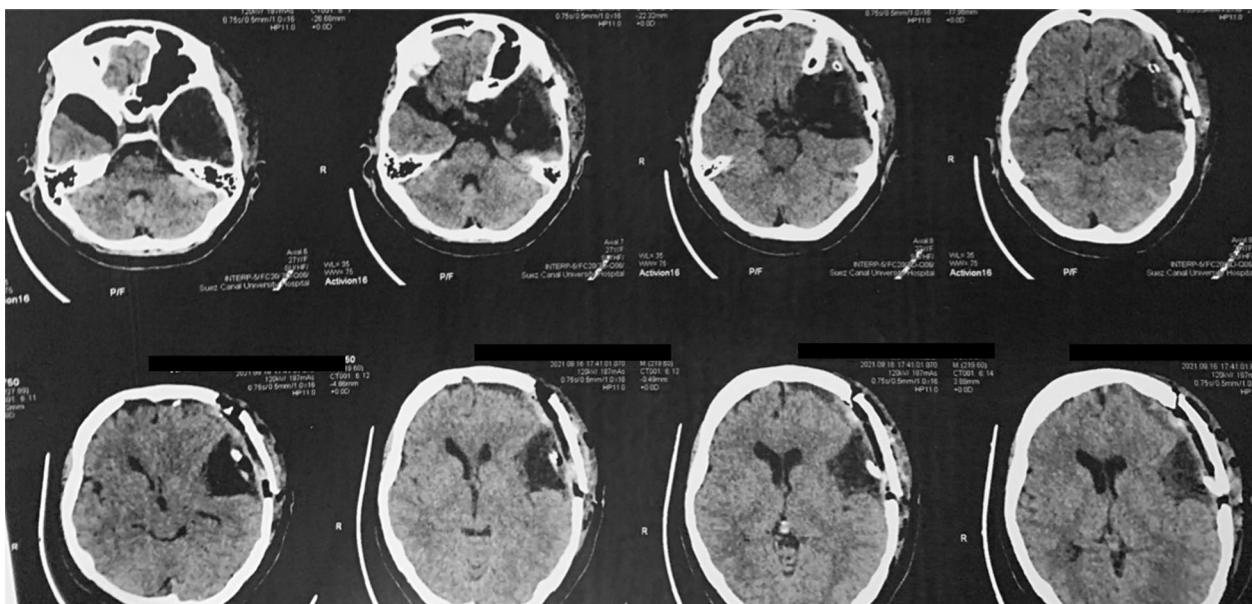


Fig. 3 Postoperative CT brain axial section day 1 showing craniotomy site with arachnoid cyst back in place in the temporal fossa; subdural drain is shown

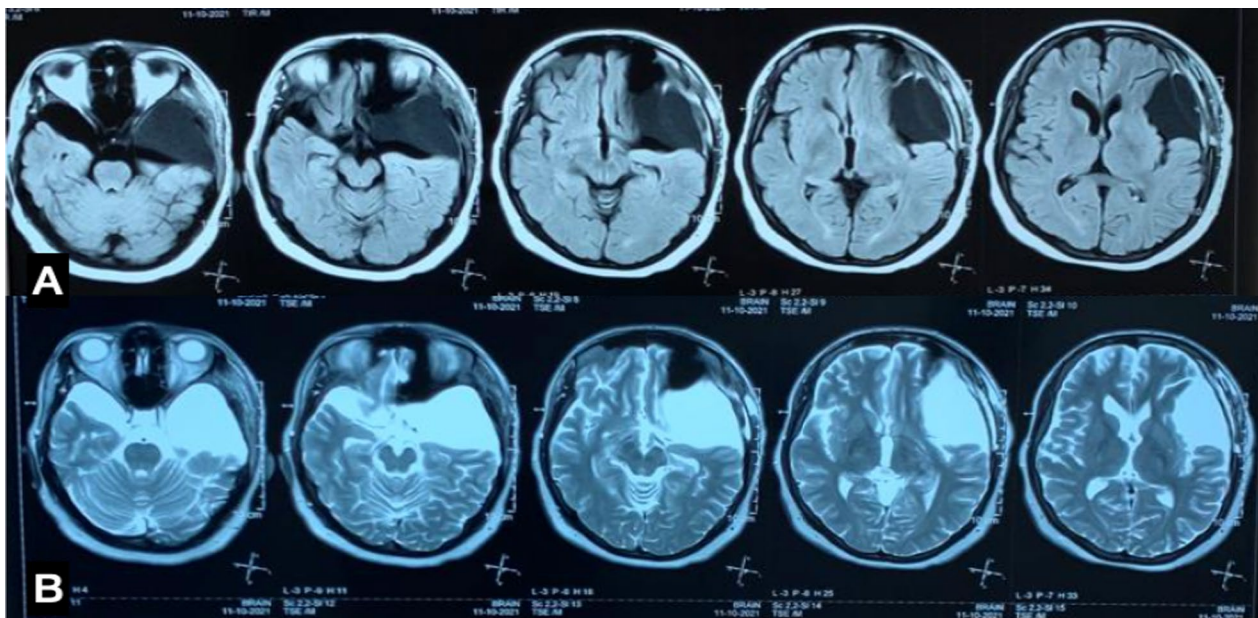


Fig. 4 Postoperative MRI brain month 1 **A** T1w axial section shows arachnoid cyst expanded in the left temporal fossa with recovery of the midline shift. **B** T2w axial section shows normal hyperintense arachnoid cyst in the left temporal fossa

condensation defect, but the exact pathogenesis is unclear [7].

Intracystic hematoma in AC was first reported in 1938 by Davidoff and Dyke [11], and it was directly linked to head trauma. Spontaneous hematoma inside AC was found to occur but the specific pathogenesis is not yet well established [7, 9, 12]. Some authors reported that the bleeding may arise from bridging veins not supported around the wall of the cyst [13]. Others referred to the idea that AC lining, which may be actively secreting CSE, results in rupture during enlargement of the AC, which could result in hemorrhage, and this is exclusive to the middle fossa AC [4, 7]. Other diseases that could cause intracystic hematoma associated with SDH are bleeding tendency, coagulative drugs, hypertension, and cancers [14].

Liu *et al.* [15] in 2019 reported that concomitant occurrence usually starts with the rupture of one or more parts of enlarging AC, resulting in blood leakage into both subarachnoid and subdural spaces. They directed the cause of cyst rupture due to several factors such as angiogenesis or inflammation.

Radiologically, intracystic hematoma in AC may mask the true radiological appearance of AC. In some patients it is very difficult to detect AC from chronic or subacute SDH or intracystic hematoma [10].

AC is only symptomatic in 5% of patients [16], and is related to the mass effect formed by AC [17]. However,

most cases of intracystic hematoma in AC are associated with symptoms such as persistent headaches, visual affection, projectile vomiting hemiparesis, and altered level of consciousness [18, 19].

The ideal management of intracystic hematoma in AC and SDH has been debated in several reports in literature, with agreement of surgical intervention resting on either craniotomy, cyst fenestration and evacuation, or burr hole evacuation. Liu *et al.* [15] in 2019 reported a 7-year-old male patient who underwent several craniotomies for a spontaneous hematoma in AC and SDH, until finally deciding to proceed conservatively with atorvastatin. They reported that it reduced inflammatory responses in rats and up regulated the expression of brain-derived neurotrophic factor (BDNF), which has an important role in the recovery in patients post-stroke and those with Alzheimer's disease. Wang *et al.* [20] also recommended the use of atorvastatin in the preparation phases of patients undergoing SDH evacuation by burr hole for similar reasons. In contrast, in the literature we found approximately 33 case reports (Table 1), most of which (31) advocated for the surgical intervention of evacuation. In this case report we opted for surgical evacuation for the patient, and she had an improvement in regard to all symptoms, with no recurrence of hematoma.

Table 1 Summary of cases reported in literature

#	Author/year	Sex/age, years	Management	Prognosis
1	Ikeda/2000 [21]	Male/57	Craniotomy + cyst evacuation	Improved
2	Ibarra/2000 [22]	Male/11	Burr hole	Improved
3	Mori/2002 [5]	Female/71	Hematoma irrigation	Improved
4	Iaconetta/2005 [12]	Male/13	Craniotomy + cyst fenestration	Improved
5	Iglesias/2006 [23]	Male/10	Craniotomy + cyst fenestration	Improved
7	Henriques/2007 [24]	Male/10	Nonsurgical	Improved
6	Hong/2008 [17]	Female/11	Craniotomy + cyst fenestration	Improved
7	Akyuz/2009 [25]	Female/40	Craniotomy + cyst fenestration	Improved
8	Patel/2009 [26]	Male/22	Craniotomy + cyst fenestration	Improved
9	Burke/2010 [27]	Female/45	Nonsurgical	Death
10	Gunduz/2010 [28]	Male/57	Craniotomy + cyst evacuation	Improved
11	Gunduz/2010 [28]	Female/19	Craniotomy + cyst evacuation	Improved
12	Wu/2010 [29]	Male/42	Burr hole	Improved
13	Arora/2014 [30]	Female/40	Craniotomy + cyst evacuation	Improved
14	Shrestha/2014 [31]	Male/21	Craniotomy + cyst evacuation	Improved
15	Chandra/2015 [32]	Male/12	Craniotomy + cyst evacuation	Improved
16	Hall/2016 [4]	Female/34	Craniotomy + cyst fenestration	Improved
17	Yuksel/2016 [33]	Male/17	Craniotomy	Improved
18	Adin/2018 [18]	Male/36	Craniotomy + cyst fenestration	Improved
19	Adin/2018 [18]	Male/21	Non-Surgical	Improved
20	Johnson/2018 [34]	Female/29	Craniotomy	Improved
21	Kaszuba/2018 [35]	Male/47	Craniotomy + cyst evacuation	Improved
22	Wu/2018 [29]	Male/8	Craniotomy + cyst evacuation	Improved
23	Wu/2018 [29]	Male/12	Craniotomy + cyst evacuation	Improved
24	Wu/2018 [29]	Male/42	Craniotomy + cyst evacuation	Improved
25	Aydogmus/2019 [19]	Male/15	Burr hole	Improved
26	Liu/2019 [15]	Male/7	Repeated surgeries followed by nonsurgical atorvastatin	Improved
27	Balestrino/2020 [36]	Male/10	Burr hole	Epidural hematoma
28	Balestrino/2020 [36]	Male/5	Burr hole + cyst fenestration	Improved
29	Balestrino/2020 [36]	Female/13	Craniotomy + cyst fenestration	Improved
30	Balestrino/2020 [36]	Male/3 months	Burr hole	Improved
31	Balestrino/2020 [36]	Male/7	Craniotomy + cyst fenestration	Improved
32	Ferreira/2021 [37]	Male/44	Craniotomy + cyst evacuation	Improved
33	Kieu [38]	Female/33	Craniotomy + cyst fenestration	Improved
34	This report/2022	Female/19	Craniotomy + cyst evacuation	Improved

Conclusion

Concomitant intracystic hematoma in AC along with SDH is a serious condition that might be life-threatening if not well managed. Several studies should be initiated to study the exact pathophysiology of this disease to build the best practice algorithm for management. In addition, the majority of authors in the literature favor surgical evacuation for the best outcome.

Abbreviations

AC	Arachnoid cyst
BDNF	Brain-derived neurotrophic factor
CSF	Cerebrospinal fluid

CT	Computed tomography
EMA	Epithelial membrane antigen
SDH	Subdural hematoma
MRI	Magnetic resonance imaging

Acknowledgements

We would like to express our gratitude to members of the Neurosurgery department at Suez Canal University for their help and support in this case report.

Author contributions

Khaled El-Sayed: conception, design, medical management. Mohamed K Elkazaz: writing, medical management.

Funding

This research did not receive any specific grant from funding agencies in the public, commercial, or not-for-profit sectors.

Availability of data and materials

The datasets used and/or analyzed during the current study are available from the corresponding author on reasonable request.

Declarations**Ethics approval and consent to participate**

In this case report we followed the World Medical Association (WMA) Declaration of Helsinki—Ethical Principles for Medical Research Involving Human Subjects. The faculty approved this report for research purpose.

Consent for publication

Written informed consent was obtained from the patient for publication of this case report and any accompanying images. A copy of the written consent is available for review by the Editor-in-Chief of this journal.

Competing interests

The authors declare that they have no known competing financial interests or personal relationships that could have appeared to influence the work reported in the paper.

Received: 27 September 2022 Accepted: 22 March 2024

Published online: 29 August 2024

References

- Van der Meche FG, Braakman R. Arachnoid cysts in the middle cranial fossa: cause and treatment of progressive and non-progressive symptoms. *J Neurol Neurosurg Psychiatry*. 1983;46:1102–7.
- Pierre-Kahn A, Capelle L, Brauner R, et al. Presentation and management of suprasellar arachnoid cysts: review of 20 cases. *J Neurosurg*. 1990;73:355–9.
- Rengachary SS, Watanabe I. Ultrastructure and pathogenesis of intracranial arachnoid cysts. *J Neuropathol Exp Neurol*. 1981;40:61–83.
- Hall A, White MAJ, Myles L. Spontaneous subdural haemorrhage from an arachnoid cyst: a case report and literature review. *Br J Neurosurg*. 2017;31:607–10.
- Mori K, Yamamoto T, Horinaka N, et al. Arachnoid cyst is a risk factor for chronic subdural hematoma in juveniles: twelve cases of chronic subdural hematoma associated with arachnoid cyst. *J Neurotrauma*. 2002;19:1017–27.
- Rashid S, Watson C, Agarwal R. Episodic headache and arachnoid cyst related subdural hematoma. *Headache*. 2016;56:1354–5.
- Krishnan P, Kartikueyan R. Arachnoid cyst with ipsilateral subdural hematoma in an adolescent—causative or coincidental: case report and review of literature. *J Pediatr Neurosci*. 2013;8:177.
- Khalid I, Godfrey AM, Ouellette DR. Chemical pneumonitis and subsequent reactive airways dysfunction syndrome after a single exposure to a household product: a case report. *J Med Case Rep*. 2009;3:1–6.
- Kwak YS, Hwang SK, Park SH, et al. Chronic subdural hematoma associated with the middle fossa arachnoid cyst: pathogenesis and review of its management. *Child's Nervous Syst*. 2013;29:77–82.
- Osborn AG, Preece MT. Intracranial cysts: radiologic-pathologic correlation and imaging approach. *Radiology*. 2006;239:650–64.
- Davidoff LM, Dyke CG. Relapsing juvenile chronic subdural hematoma. A clinical and roentgenographic study. *Bull Neurol Inst NY*. 1938;7:95–111.
- Iaconetta G, Esposito M, Maiuri F, et al. Arachnoid cyst with intracystic haemorrhage and subdural haematoma: case report and literature review. *Neurol Sci*. 2006;26:451–5.
- Galassi E, Piazza G, Gaist G, et al. Arachnoid cysts of the middle cranial fossa: a clinical and radiological study of 25 cases treated surgically. *Surg Neurol*. 1980;14:211–9.
- O'Brien DF, Basu S, O'Donnell JR, et al. The impact of aspirin therapy and anticoagulation on the prevalence of spontaneous subdural haematoma. *Int Med J*. 2000;93:244–6.
- Liu B, Wang C, Qu Y. Treatment of arachnoid cyst with spontaneous hemorrhage with atorvastatin. *Front Pharmacol*. 2019;10:1343.
- Al-Holou WN, Terman S, Kilburg C, et al. Prevalence and natural history of arachnoid cysts in adults. *J Neurosurg*. 2013;118:222–31.
- Hong J-C, Kim M-S, Chang C-H, et al. Arachnoid cyst with spontaneous intracystic hemorrhage and chronic subdural hematoma. *J Korean Neurosurg Soc*. 2008;43:54.
- Adin ME, Yildiz MS, Deniz MA, et al. Arachnoid cysts with spontaneous intracystic hemorrhage and associated subdural hematoma: report of management and follow-up of 2 cases. *Radiol Case Rep*. 2018;13:516–21.
- Aydogmus E, Hicdonmez T. Spontaneous intracystic haemorrhage of an arachnoid cyst associated with a subacute subdural hematoma: a case report and literature review. *Turk Neurosurg*. 2017;17:1–5.
- Tang R, Shi J, Li X, et al. Effects of atorvastatin on surgical treatments of chronic subdural hematoma. *World Neurosurg*. 2018;117:e425–9.
- Ikeda H, Deinsberger W, Böker DK. Retroclival arachnoid cyst presenting with spontaneous intracystic haemorrhage—case presentation. *Acta Neurochir (Wien)*. 2000;142:1317.
- Ibarra R, Kesava PP. Role of MR imaging in the diagnosis of complicated arachnoid cyst. *Pediatr Radiol*. 2000;30:329–31.
- Iglesias A, Arias M, Mejjide F, et al. Quiste aracnoideo complicado con hemorragia intraquistica y hematoma subdural espontáneo: hallazgos en resonancia magnética. *Radiología*. 2006;48:245–8.
- de Henriques JGB, Pianetti Filho G, Henriques KSW, et al. Spontaneous acute subdural hematoma contralateral to an arachnoid cyst. *Arq Neuropsiquiatr*. 2007;65:1034–6.
- Akyuz M, Goksu E, Aralasmak A, et al. Retroclival arachnoid cyst presenting with haemorrhage: a brief report of a special case. *Acta Neurochir (Wien)*. 2010;152:161–2.
- Patel AP, Oliverio PJ, Kurtom KH, et al. Spontaneous subdural hematoma and intracystic hemorrhage in an arachnoid cyst. *Radiol Case Rep*. 2009;4:298.
- Burke MP, O'Donnell C, Opeskin K. Spontaneous acute subdural hematoma complicating arachnoid cyst. *Am J Forensic Med Pathol*. 2010;31:382–4.
- Gunduz B, Yassa MK, Ofluoglu E, et al. Two cases of arachnoid cyst complicated by spontaneous intracystic hemorrhage. *Neurol India*. 2010;58:312.
- Wu X, Li G, Zhao J, et al. Arachnoid cyst—associated chronic subdural hematoma: report of 14 cases and a systematic literature review. *World Neurosurg*. 2018;109:e118–30.
- Arora R, Puligopu AK, Uppin MS, et al. Suprasellar arachnoid cyst with spontaneous intracystic hemorrhage: a rare complication—role of MR and illustration of a case. *Pol J Radiol*. 2014;79:422.
- Shrestha R, You C. Spontaneous chronic subdural hematoma associated with arachnoid cyst in children and young adults. *Asian J Neurosurg*. 2014;9:168.
- Chandra VVR, Prasad BC, Subramaniam CS, et al. Spontaneous intracystic hemorrhage complicating an intracranial arachnoid cyst. *J Neurosci Rural Pract*. 2015;6:629–30.
- Yüksel MO, Gürbüz MS, Senol M, et al. Spontaneous subdural haematoma developing secondary to arachnoid cyst rupture. *J Clin Diagn Res*. 2016;10:PD05.
- Johnson R, Amine A, Farhat H. Spontaneous acute subdural hematoma associated with arachnoid cyst and intra-cystic hemorrhage. *Cureus*. 2018;10:e3383.
- Kaszuba MC, Tan LA, Moftakhar R, et al. Nontraumatic subdural hematoma and intracystic hemorrhage associated with a middle fossa arachnoid cyst. *Asian J Neurosurg*. 2018;13:116.
- Balestrino A, Piatelli G, Consales A, et al. Spontaneous rupture of middle fossa arachnoid cysts: surgical series from a single center pediatric hospital and literature review. *Child's Nervous Syst*. 2020;36:2789–99.
- Ferreira TSH, Malveira LRC, Neto AG. Spontaneous subdural and intracystic hemorrhage of temporal arachnoid cyst in an adult patient. *Interdiscip Neurosurg*. 2021;23: 100830.
- Kieu HD, Le TD, Tran TQ. Arachnoid cyst with spontaneous intracystic hemorrhage and associated chronic subdural hematoma: a case report. *Int J Surg Case Rep*. 2021;81: 105789.

Publisher's Note

Springer Nature remains neutral with regard to jurisdictional claims in published maps and institutional affiliations.