

CASE REPORT

Open Access



Fistulising skin metastases in Crohn's disease: a case report and review of the literature

Tanja Elger^{1*}, Johanna Loibl¹, Christa Buechler¹, Sebastian Haferkamp³, Jens Werner², Konstantin Drexler³, Ulrich Hohenleutner³, Karsten Guelow¹, Claudia Kunst¹, Arne Kandulski¹, Pia Goeggelmann¹, Martina Mueller¹ and Hauke Christian Tews¹

Abstract

Background Metastatic Crohn's disease is a rare disorder characterized by various granulomatous skin lesions that occur independently of gastrointestinal tract involvement. However, currently there is no standardized care or specific treatment. Therapeutic approaches include immunosuppressive agents, such as corticosteroids, azathioprine, and monoclonal antibodies targeting inflammatory cytokines like tumor necrosis factor (TNF).

Case presentation We present a case of a 29-year-old western European woman with significant blind ending abdominal subcutaneous fistulas and abscesses, who sought evaluation in the dermatology department. Histological examination revealed multiple epithelioid cell granulomas. There was no evidence of infectious or rheumatologic diseases such as sarcoidosis. The tentative diagnosis was metastatic Crohn's disease, which was not related to an intestinal manifestation of the disease. The patient responded to infliximab but had to discontinue it due to an allergic reaction. Subsequent adalimumab treatment failed to induce clinical remission; thus, therapy was switched to ustekinumab, resulting in a positive response. Written informed consent for publication of their clinical details and clinical images was obtained from the patient.

For our study more than 1600 publications were screened for cases of metastatic Crohn's disease on PubMed database. 59 case reports with 171 patients were included in the analysis and evaluated for localization, diagnostic and therapeutic approaches, and complications and were summarized in this review.

Conclusion The successful ustekinumab treatment of a patient with metastatic Crohn's disease underscores the potential of this minimally investigated therapeutic option, highlighting the need for future treatment guidelines given the increasing prevalence of such cases.

Keywords Metastatic Crohn's disease, Skin fistulae, Ustekinumab, Inflammatory bowel disease, Extraintestinal manifestation

*Correspondence:

Tanja Elger

tanja.elger@klinik.uni-regensburg.de

Full list of author information is available at the end of the article



© The Author(s) 2024. **Open Access** This article is licensed under a Creative Commons Attribution 4.0 International License, which permits use, sharing, adaptation, distribution and reproduction in any medium or format, as long as you give appropriate credit to the original author(s) and the source, provide a link to the Creative Commons licence, and indicate if changes were made. The images or other third party material in this article are included in the article's Creative Commons licence, unless indicated otherwise in a credit line to the material. If material is not included in the article's Creative Commons licence and your intended use is not permitted by statutory regulation or exceeds the permitted use, you will need to obtain permission directly from the copyright holder. To view a copy of this licence, visit <http://creativecommons.org/licenses/by/4.0/>. The Creative Commons Public Domain Dedication waiver (<http://creativecommons.org/publicdomain/zero/1.0/>) applies to the data made available in this article, unless otherwise stated in a credit line to the data.

Background

Metastatic Crohn's disease is a rare disease that primarily affects patients diagnosed with inflammatory bowel diseases (IBD). In rare cases, cutaneous manifestations precede gastrointestinal involvement. It most commonly occurs in the genital region, but can also affect every other part of the body. The lesions present as plaques, ulcers, fissures or papules [1] and, in rare cases, as fistulas. They are often asymptomatic but may also cause pain or itching. Despite the misleading wording, metastatic Crohn's disease is not considered an oncologic entity. Instead, the term "metastatic" refers to the involvement of sites with no physical connection to the GI-tract. Metastatic Crohn's disease must not be mixed up with extraintestinal manifestations of Crohn's disease. Whereas extraintestinal manifestations such as pyoderma gangraenosum and erythema nodosum represent distinct immunologic phenomena, metastatic Crohn's disease exhibits the same histological findings as intestinal Crohn's disease, but on other organ sites.

Usually, a biopsy from the involved site is required for the diagnosis of metastatic Crohn's disease. Histological findings show non-caseating, sarcoid-like granulomas, Langerhans giant cells and foreign body giant cells surrounded by inflammatory histiocytes, plasma cells and lymphocytes [2]. For a confirmed diagnosis of metastatic Crohn's disease, other causes for granulomatous disorders have to be excluded, especially cutaneous sarcoidosis, tuberculosis, syphilis, mycobacterial infections, actinomycosis, deep fungal infections, lymphogranuloma venereum and granuloma inguinale. Also non-granulomatous skin lesions such as hidradenitis suppurativa, pyoderma gangrenosum, impetigo, erythema nodosum, factitial dermatitis from factitial injection of foreign substances, schistosomiasis, chronic lymphedema resulting from obstruction, erysipelas, chronic cellulitis and foreign body reaction need to be ruled out [3].

To objectively assess intestinal involvement, endoscopy of the upper and lower GI tract along with an abdominal magnetic resonance imaging (MRI) scan should be performed.

Currently, there is no standardized treatment of metastatic Crohn's disease and no German or European guideline, especially for cases without GI involvement. Only individual case reports exist regarding the therapeutic use of approved medication for intestinal Crohn's disease in metastatic conditions, including steroids, anti-TNF antibodies, azathioprine, and antibiotic therapy [4–7].

Ustekinumab is a human monoclonal IgG1 κ -antibody, which binds specifically to the p40-subunit of interleucine 12 (IL-12) and interleucine 23 (IL-23). The bioactivity of IL-12 and IL-23 is inhibited by ustekinumab by preventing the p40 subunit from binding to

IL-12R β 1-receptorprotein on the surface of immune cells. It is assumed that hereby the cytokine pathways of Th1- and Th17-cells are interrupted, which both play an important role in the pathogenesis of Crohn's disease [8].

We here report a case of metastatic Crohn's disease successfully treated with ustekinumab at our university hospital and provide a literature review on the current therapeutic options for metastatic Crohn's disease.

Case report

In 2020, a 29-year-old western European woman presented to the dermatology department of our university hospital with pronounced abdominal blind-ending fistulas. The initial patient contact was documented in 2019 when she sought care at the emergency department with multiple recurrent abscesses of the abdominal skin that first appeared after a tick bite a few weeks prior.

Between January 2019 and July 2020, multiple incisions of recurrent abscesses were performed in combination with antibiotic treatment. However, complete healing was not achieved. Instead, the abscess cavities expanded beneath the skin, subsequently forming a system of connected fistulas (Fig. 1), as visualized in MRI enterography (Fig. 2).

When the patient presented to the dermatology department in 2020, the fistulas showed active inflammation with secretion and were almost 2 cm in diameter. In addition, a blind ending subcutaneous fistula of the thigh could be detected, which also showed active inflammation and secretion.

Histologic examination revealed a granulomatous infiltrate with histiocytes and multinuclear giant cells, forming granulomas. In addition, lymphocytes, plasma cells, neutrophils, and eosinophils, and a granulomatous

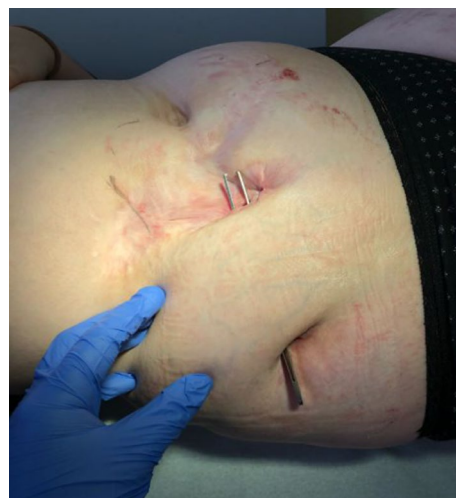

Fig. 1 Large subcutaneous fistula, 2020

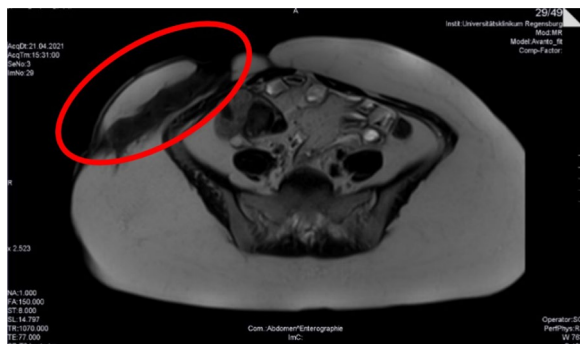

Fig. 2 MRI enterography of the large subcutaneous abdominal fistula (red circle), April 2021

perivasculitis were observed (Fig. 3). Differential diagnoses of granulomatous diseases such as sarcoidosis, tuberculosis and immunodeficiencies were ruled out, confirming the diagnosis of metastatic Crohn's disease.

To investigate intestinal involvement, abdominal MRI, gastroscopy, and colonoscopy were performed. However, these examinations did not reveal any gastrointestinal involvement at this time. Moreover, fecal calprotectin levels were normal. There was no history of inflammatory bowel disease in the patient's family.

Antibiotic therapy had failed in the past, but the Patient responded well to prednisolone. As maintenance therapy for metastatic Crohn's disease, the patient initially received infliximab at a dosage of 5 mg/kg. The patient responded well to this therapy, leading to the cessation of fluid secretion by the fistulas. However, an allergic reaction with dyspnea and rash occurred after the 10th dose of infliximab in October 2021, necessitating the discontinuation of treatment.

To evaluate further treatment options, the patient was referred to the department of Gastroenterology in November 2021. Meanwhile, she had developed diarrhea

and abdominal pain. MRI revealed a mild ileitis, which, however, could not be validated by colonoscopy.

Therapy was switched to adalimumab in December 2021, to which the patient did not respond. Instead, a new fistula ostium developed.

Despite the lack of evidence for ustekinumab therapy in metastatic Crohn's disease, and given its established efficacy only for intestinal manifestation, treatment with ustekinumab was initiated in May 2022 with an initial dose of 390 mg intravenous, followed by 90 mg subcutaneous every 8 weeks. This decision was based on the suspicion that the inflammatory processes in the abdominal fistula mirrored those seen in intestinal inflammation. The patient responded well and inflammation decreased within a few weeks. However, fistulas persisted, albeit with reduced secretion.

In June 2022, the blind-ending subcutaneous fistula of the thigh could be successfully treated by surgery after the active inflammation resolved. In April 2023, the abdominal fistula also showed no remaining inflammation, so a complete excision of the abdominal fistulas was performed. At the patient's last visit in August 2023, no new fistula or abscesses were detected, but ustekinumab was continued due to the long and complicated clinical history. Written informed consent for publication of their clinical details and clinical images was obtained from the patient.

Review of the current literature

Material and methods

A data base literature search was performed using the keywords "metastatic" and "Crohn's" and "disease". 1,875 reports published from January 2012 to November 2023 were found. The number of papers meeting the search criteria steadily increased, highlighting the clinical relevance of this topic.

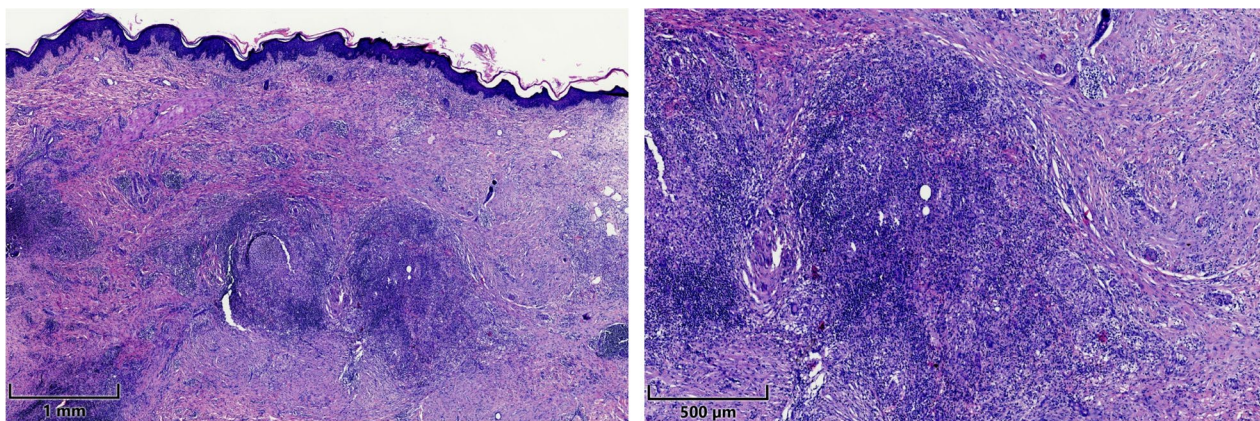


Fig. 3 Histologic examination of a fistula biopsy showing granulomas with histiocytes and multinuclear giant cells, July 2020

So far, 59 case reports including 171 patients and 12 reviews about clinical presentation, diagnostic approach and therapeutic options have been published. However, no statistical analysis of patient characteristics and treatments is available. Therefore, our aim was to objectively assess these items. Moreover, we intended to discuss ustekinumab as a novel but successful therapeutic approach for metastatic Crohn’s disease.

Results

Of the patients with metastatic Crohn’s disease, 74% were female, and 38% of the cases involved individuals under 18 years old. From this cohort, we assessed diagnostic and therapeutic approaches for metastatic Crohn’s disease.

80% of the patients were diagnosed with intestinal Crohn’s disease before or at the time skin lesions appearance, while 10% exhibited gastrointestinal symptoms such as diarrhea or abdominal pain without IBD [9–19]. 7% had isolated extraintestinal manifestations as illustrated in our presented case. Fistulas were described in 13% of all cases [4, 20–22], highlighting the rarity of this condition. However, fistula presence or absence was not explicitly mentioned in 58% of all published cases.

At the time of diagnosing metastatic Crohn’s disease, usually skin biopsies are taken and examined. Granulomas were present in 58% of all cases [3–7, 10–17, 19–46], with some studies not commenting on histological findings.

(Fig. 4).

The most common localization of metastatic Crohn’s disease was the genital region, including groin, vulva and penis/scrotum (Fig. 5). Notably, our case report highlights that metastatic Crohn’s disease can affect almost every part of the body. This is in accordance with other reports describing affected skin at various sites of the

body including extremities, trunk or head/face [4, 5, 16, 22, 25, 30–32, 36–38, 41, 44, 47, 48].

Less common sites of involvement included intraabdominal abscesses [31, 49] and necrotizing endocarditis of the aortic valve with granuloma formation [26]. Some patients also exhibited lesions on more than one site. They were counted for each site in Fig. 5. For 12 patients, the site of involvement was not mentioned.

There are no general recommendations for the treatment of metastatic Crohn’s disease, but similar pathophysiological processes are suspected. Hence, established therapeutic regimens for the treatment of intestinal Crohn’s disease are employed. The most common therapeutic approach involves corticosteroid admission (Figure 6), often resulting in a lesion reduction. Anti-TNF, especially infliximab, was effective and utilized in 41.6% of cases. Some patients received multiple therapies and were counted accordingly (Fig. 6).

Steroid treatment led to remission or improvement in 30.8% of all described cases (Table 1). Excluding unknown cases, steroids induced remission (17.2%) or improvement (55.2%) in 72.4% of patients.

Anti-TNF, especially infliximab, less common also adalimumab and certolizumab, only had an effect (improvement or remission) in 15.6% of the cases. However, excluding unknown cases, remission was induced in 13.3% and improvement in 53.3% of patients (Table 1).

Antibiotics, azathioprine and topical tacrolimus also showed positive effects, although azathioprine did not induce remission in any patient. Data regarding surgical interventions, mesalazine, anti-TNF plus azathioprine, MTX/6-MP, ustekinumab, and hyperbaric oxygen therapy are limited and inconclusive based on the literature. Notably and in line with the presented case, two out of three patients achieved remission after treatment with ustekinumab.

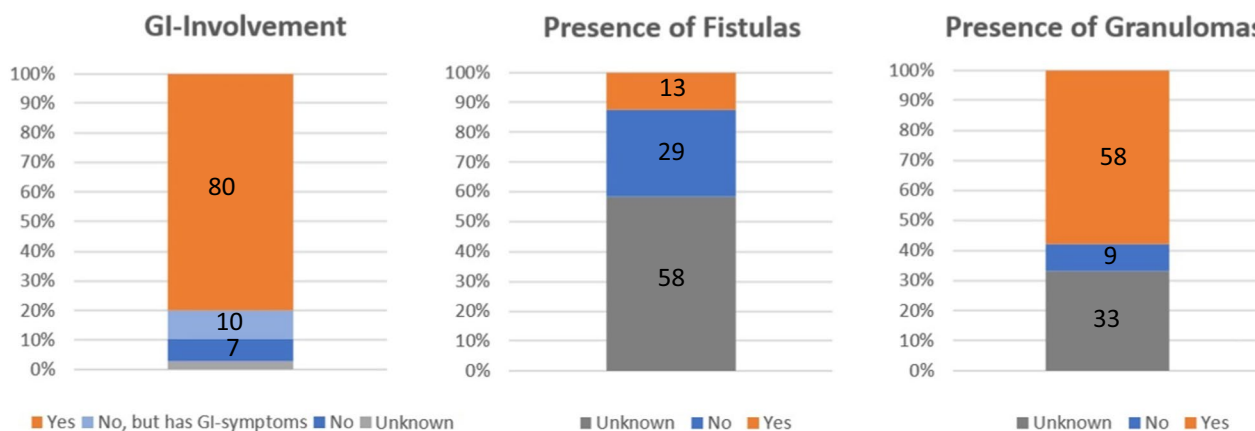


Fig. 4 Proportion of patients with GI-Involvement, granuloma and fistula (n = 171)

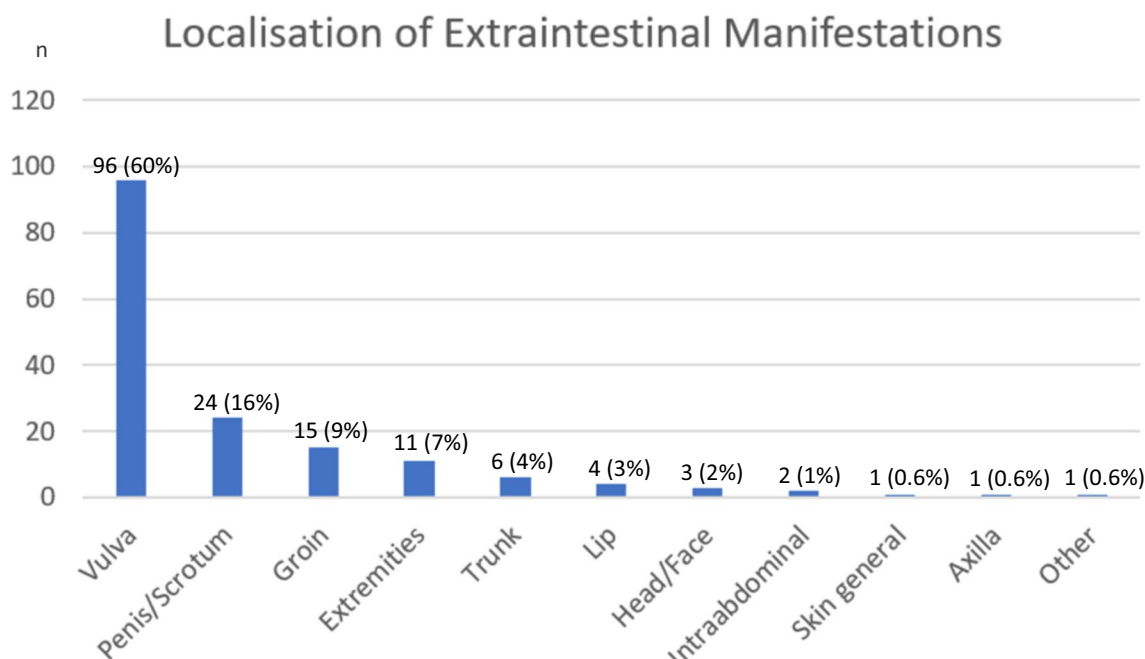


Fig. 5 Localisation of lesions in patients with metastatic Crohn’s disease (n = 159)

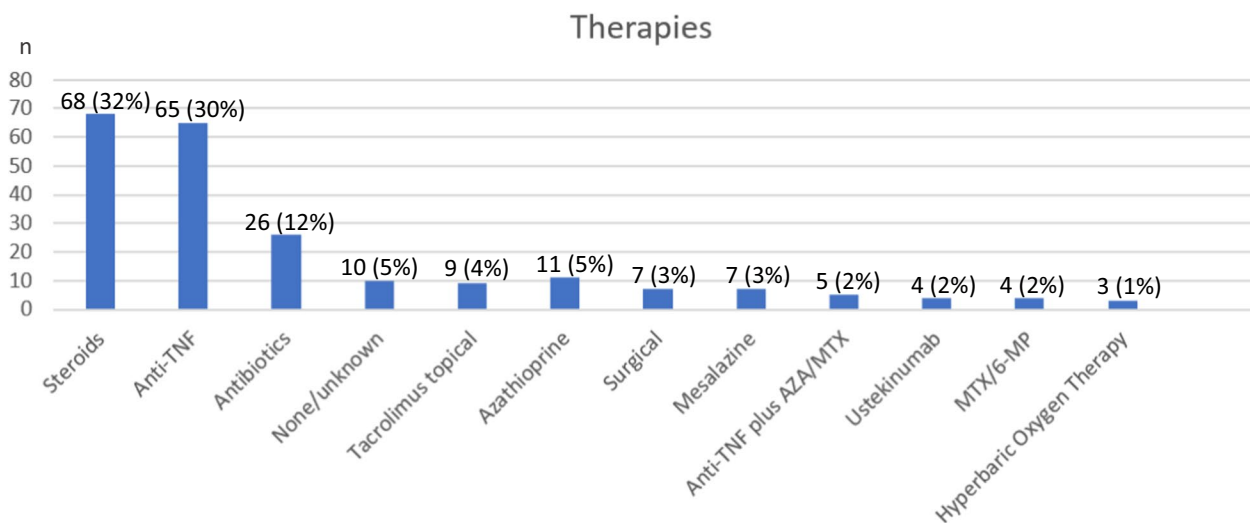


Fig. 6 Therapeutic approaches for metastatic Crohn’s disease (n = 219)

Discussion

Our examination summarizes patient characteristics in metastatic Crohn’s disease and outlines therapeutic options based on the presented case. However, there are some limitations.

We established the diagnosis of metastatic Crohn’s diseases based on clinical and histological findings. Other granulomatous diseases such as sarcoidosis, tuberculosis and immunodeficiencies were ruled out, and histological

findings were typical for Crohn’s lesions despite there was no intestinal involvement at the time of diagnosis. However, there is no possibility of completely ruling out any other underlying immunological condition causing similar symptoms. The analyzed case reports mostly also based their diagnosis on histological findings fitting Crohn’s criteria, and often on a known underlying intestinal Crohn’s disease, but in some publications, diagnostic criteria were not discussed in detail.

Table 1 Response to therapeutic options

Response	None, n (%)	Remission n (%)	Improvement n (%)	Worsening n (%)	Unknown n (%)	Total n (%)
Steroids	6 (9.1)	5 (7.6)	16 (24.2)	2 (3.0)	37 (56.1)	66 (100)
Anti-TNF	5 (7.8)	2 (3.1)	8 (12.5)	0 (0)	49 (76.6)	64 (100)
Antibiotics	5 (22.7)	4 (18.2)	8 (36.4)	1 (4.5)	4 (18.2)	22 (100)
None/unknown	0 (0)	0 (0)	0 (0)	0 (0)	10 (100)	10 (100)
Tacrolimus topical	3 (33.3)	0 (0)	5 (55.6)	0 (0)	1 (11.1)	9 (100)
Azathioprine	0 (0)	3 (33.3)	4 (44.4)	0 (0)	2 (22.2)	9 (100)
Surgical	2 (28.6)	1 (14.3)	1 (14.3)	0 (0)	3 (42.9)	7 (100)
Mesalazine	0 (0)	2 (28.6)	2 (28.6)	1 (14.3)	2 (28.6)	7 (100)
Anti-TNF plus AZA/MTX	1 (25.0)	0 (0)	2 (50.0)	1 (25.0)	0 (0)	4 (100)
Ustekinumab	0 (0)	2 (66.7)	1 (33.3)	0 (0)	0 (0)	3 (100)
MTX/6-MP	1 (25.0)	1 (25.0)	0 (0)	0 (0)	2 (50.0)	4 (100)
Hyperbaric Oxygen Therapy	1 (33.3)	1 (33.3)	1 (33.3)	0 (0)	0 (0)	3 (100)

N, number of patients; %, percentage of response of all patients [3–7, 9–63]

Our analysis is a summary of published cases and no randomized trial, making it impossible to compare the efficiencies of different therapies. This article outlines various treatment approaches and their success rates according to literature data. However, assessing the patient's condition before and after treatment from literature data can be challenging.

Several patients responded well to antibiotic treatment (see Table 1). This was also effective in some patients with GI involvement. Nevertheless, it remains unclear if lesions described as metastatic Crohn's disease are infectious or a manifestation of Crohn's disease.

Despite these limitations, treatments for metastatic Crohn's disease could be evaluated. The most effective treatments, according to the current literature, include steroids and anti-TNF-antibodies. Despite the small number of cases, also azathioprine showed good clinical results. Mesalazine also appeared to positively impact skin lesions in patients with metastatic Crohn's disease (see Table 1).

Conclusively, mesalazine, azathioprine, steroids, and anti-TNF antibodies should be considered as first line therapy for metastatic Crohn's disease.

In case of treatment failure, there are less common therapeutic options such as ustekinumab, surgical intervention or hyperbaric oxygen therapy, which can be offered to the patient. Although the efficacy cannot be evaluated based on the limited amount of available data, the existing literature as well as our case report suggests a positive effect of ustekinumab in patients with metastatic Crohn's disease.

Topical tacrolimus can improve the lesions, but there is no case report where topical tacrolimus could induce remission [3, 5, 9, 24, 39, 57, 61], and can currently not be

recommended as a single therapeutic option. It might be useful to support other therapies.

Conclusion

Metastatic Crohn's disease can affect patients with or without GI involvement. Diagnostics include anamnesis, inspection and biopsies of the involved site as well as endoscopy and MRI.

Currently, with no German, European or American guidelines available, approved therapies for intestinal Crohn's disease are employed, based on the suspected similar inflammatory pathophysiology in intestinal and extraintestinal sites: Steroids, anti-TNF antibodies, and antibiotics were the primary and most potent agents. Mesalazine and azathioprine as well as less common treatment options such as surgical intervention or hyperbaric oxygen therapy may also be considered in case of treatment failure.

With the increasing number of reported cases of metastatic Crohn's disease, the need for future guidelines for treating these patients becomes apparent. Our case demonstrates successful ustekinumab treatment for metastatic Crohn's disease, suggesting a potential new therapeutic option.

Acknowledgements

Not applicable.

Author contributions

HCT initiated the project and designed the work; TE and HCT were responsible for case preparation; TE drafted the manuscript; TE, JL, CB, SH, JW, KD, UH, AK, PG, and HCT analyzed results; TE performed literature search; TE prepared figures; TE, CK, KG, MMS, and HCT wrote and edited the manuscript. All authors approved the final version of the manuscript.

Funding

Open Access funding enabled and organized by Projekt DEAL. This study received no funding.

Availability of data and materials

Laboratory results, histological findings, imaging and other diagnostic results are available if necessary.

Declarations**Ethical approval and consent to participate**

See section below.

Consent for publication

Written informed consent for publication of their clinical details and clinical images was obtained from the patient. A copy of the written consent is available for review by the Editor-in-Chief of this journal.

Competing interests

All authors declare no competing interests.

Author details

¹Department of Internal Medicine I, Gastroenterology, Hepatology, Endocrinology, Rheumatology and Infectious Diseases, University Hospital Regensburg, Franz-Josef-Strauß-Allee 11, 93053 Regensburg, Germany. ²Department of Visceral Surgery, University Hospital Regensburg, Regensburg, Germany. ³Department of Dermatology, University Hospital Regensburg, Regensburg, Germany.

Received: 2 February 2024 Accepted: 10 April 2024

Published online: 19 May 2024

References

- Ickrath F, Stoevesandt J, Schulmeyer L, Glatzel C, Goebeler M, Kerstan A. Metastatic Crohn's disease: an underestimated entity. *J Dtsch Dermatol Ges.* 2021;19(7):973–82.
- Kurtzman DJB, Jones T, Lian F, Peng LS. Metastatic Crohn's disease: a review and approach to therapy. *J Am Acad Dermatol.* 2014;71(4):804–13.
- Aberumand B, Howard J, Howard J. Metastatic Crohn's disease: an approach to an uncommon but important cutaneous disorder. *Biomed Res Int.* 2017;2017:8192150.
- Ballester Sánchez R, Sanchís Sánchez C, Rodrigo Nicolás B, Valcuende CF. Enfermedad de Crohn metastásica tratada con ustekinumab. *Actas Dermosifiliogr.* 2021;112(2):182–3.
- Blasco Alonso J, Girón Fernández-Crehuet F, Lendínez Ramírez MA, Gallego Gutiérrez S, Luque Pérez S, Serrano Nieto J, et al. Metastatic Crohn's disease in pediatrics. *Rev Esp Enferm Dig.* 2016;108(9):598–603.
- Kapur SV, Oswal JS, Viswanathan V. Vulval edema as a manifestation of childhood metastatic Crohn's disease. *Indian J Pediatr.* 2021;88(2):182. <https://doi.org/10.1007/s12098-020-03419-4.pdf>.
- Kyriakou G, Gkempesi M, Thomopoulos K, Marangos M, Georgiou S. Metastatic vulvar Crohn's disease preceding intestinal manifestations: a case report and short review. *Acta Dermatovenerol Alp Pannonica Adriat.* 2019;28(3):131–3.
- Janssen Cilag International, editor. Fachinformation Ustekinumab. 2023.
- Barrick BJ, Tollefson MM, Schoch JJ, McEvoy MT, Hand JL, Wieland CN, et al. Penile and scrotal swelling: an underrecognized presentation of Crohn's disease. *Pediatr Dermatol.* 2016;33(2):172–7.
- Gulseren D, Ersoy-Evans S. Metastatic Crohn disease with groin localization in an adult patient. *Dermatol Pract Concept.* 2022;12(2): e2022056.
- Kim S, Won YB, Seo SK, Cho S, Choi YS, Lee BS, et al. Vulvar Crohn's disease in an adolescent diagnosed after unsuccessful surgical treatment. *BMC Womens Health.* 2021;21(1):316.
- Lanka P, Lanka LR, Sylvester N, Lakshmi MD, Ethirajan N. Metastatic Crohn's disease. *Indian Dermatol Online J.* 2014;5(1):41–3.
- Mazzoni D, Bodapati S, Mortimore R, Davies J, Wheller L. Metastatic Crohn's disease in a boy presenting with genital swelling. *Pediatr Dermatol.* 2020;37(6):1165–6.
- Mirheydar HS, Friedlander SF, Kaplan GW. Prepubertal male genitourinary metastatic Crohn's disease: report of a case and review of literature. *Urology.* 2014;83(5):1165–9.
- Pérez-Santiago L, García-Vázquez A, Martín-Arévalo J. A diagnostic challenge: chronic cutaneous ulcers as an isolated clinical finding in metastatic Crohn's disease. *Rev Esp Enferm Dig.* 2022. <https://doi.org/10.17235/reed.2022.8995/2022>.
- Saito K, Iwata Y, Nakajima Y, Numata S, Sugiura K. Metastatic Crohn's disease in childhood: a case report. *J Dermatol.* 2018;45(7):e199–200.
- Schneider SL, Foster K, Patel D, Shwayder T. Cutaneous manifestations of metastatic Crohn's disease. *Pediatr Dermatol.* 2018. <https://doi.org/10.1111/pde.13565>.
- Vahabi-Amlashi S, Molkara S, Shahrokhi Y. Cutaneous Crohn disease without intestinal manifestations. *Adv Biomed Res.* 2021;10:39.
- Rani U, Russell A, Tanaka S, Correa H, Nicholson MR. Urogenital manifestations of metastatic Crohn's disease in children: case series and review of the literature. *Urology.* 2016;92:117–21.
- Batra J, Goraya SK, Grewal S, Singh A. Metastatic Crohn's Disease of the Vulva: A Rare Presentation. *Indian Dermatol Online J.* 2020;11(3):416–8.
- Farkas K, Nagy F, Kovács L, Wittmann T, Molnár T. Anti-tumor necrosis factor- α induced systemic lupus erythematosus in a patient with metastatic Crohn's disease—what is the role of anti-TNF antibody? *J Crohns Colitis.* 2013;7(4):e143–5.
- Adachi A, Komine M, Murata S, Ohtsuki M. Japanese case of metastatic cutaneous Crohn's disease of the groin. *J Dermatol.* 2015;42(2):224–5.
- AlAsmari A, AlEssa R, AlAjroush W, AlKhodair R, AlHaddad S. Novel association of metastatic Crohn's disease and Wolman disease. *JAAD Case Rep.* 2022;20:40–3.
- Campos S, Coutinho I, Cardoso JC, Portela F. Metastatic Crohn's disease despite infliximab therapy. *An Bras Dermatol.* 2017;92(5 Suppl 1):104–6.
- Gettigan NM, Sheehan M, Slattery E. Metastatic Crohn's disease of the aortic valve resulting in severe aortic insufficiency, non-infective endocarditis, and pericarditis. *Inflamm Bowel Dis.* 2019;25(10):e117–8.
- Guglielmetti A, Gompertz M, Jahr C, Silva T, González S. Remission of refractory metastatic Crohn's disease achieved with dapsone. *Int J Dermatol.* 2018;57(4):467–9.
- Hogan N, Byrnes V, Hussey A, Joyce M. Surgical management of gluteal metastatic cutaneous Crohn's disease. *J Crohns Colitis.* 2012;6(5):617–20.
- Ishida M, Iwai M, Yoshida K, Kagotani A, Okabe H. Metastatic Crohn's disease accompanying granulomatous vasculitis and lymphangitis in the vulva. *Int J Clin Exp Pathol.* 2013;6(10):2263–6.
- Kiuru M, Camp B, Adhami K, Jacob V, Magro C, Wildman H. Treatment of metastatic cutaneous Crohn disease with certolizumab. *Dermatol Online J.* 2015;21(11):4.
- Labidi A, Karoui S, Ben Mustapha N, Serghini M, Azzoug H, Allouche W, et al. Cutaneous metastatic Crohn's disease of the abdominal wall: an exceptional location. *Tunis Med.* 2013;91(6):424–5.
- Lang N, Hartschuh W, Enk A, Toberer F. Metastatic Crohn's disease: a diagnostic and therapeutic challenge. *J Dtsch Dermatol Ges.* 2015;13(6):571–4.
- Lansdorp CA, Buskens CJ, Gecse KB, D'Haens GR, van Hulst RA. Wound healing of metastatic perineal Crohn's disease using hyperbaric oxygen therapy: a case series. *United Eur Gastroenterol J.* 2020;8(7):820–7.
- Lim Y, Singh M. Metastatic vulvar Crohn's disease with good outcome on Ustekinumab. *Cureus.* 2021;13(7): e16252.
- Math CJ, George A. Vegetating plaques in the groin: a manifestation of metastatic Crohn's disease. *Indian J Dermatol.* 2018;63(4):338–41.
- Misago N, Narisawa Y. Erythema induratum (nodular vasculitis) associated with Crohn's disease: a rare type of metastatic Crohn's disease. *Am J Dermatopathol.* 2012;34(3):325–9.
- Park HC, Kim HW, Park CG, Ko JY. Metastatic Crohn disease clinically reminiscent of erythema nodosum on the right leg. *Cutis.* 2016;98(3):E11–5.

38. Patel AV, Jones DM, Hill JC, MacDermott RP. Development of metastatic Crohn's disease of the skin while on anti-TNF biologics. *Inflamm Bowel Dis.* 2012;18(6):1188–90.
39. Pérez-Belmonte LM, Gómez-Moyano E. Metastatic Crohn's disease. *Indian J Med Res.* 2015;142(4):497.
40. Pousa-Martínez M, Alfigeme F, de Domingo González MA, Suárez-Masa D, Calvo M, Roustán G. Vulvar metastatic Crohn disease: clinical, histopathological and ultrasonographic findings. *Dermatol Online J.* 2017;23(11):21.
41. Ruiz-Villaverde R, Sánchez-Cano D, Perez-Lopez I, Aneiros-Fernández J. Enfermedad de Crohn metastásica. *Actas Dermosifiliogr.* 2017;108(2):171–2.
42. Sabbadini C, Banzato C, Schena D, Peroni D, Girolomoni G. Metastatic Crohn's disease in childhood. *J Deutsche Derma Gesell.* 2016. <https://doi.org/10.1111/ddg.12861>.
43. Sackett DD, Meshekow JS, Figueroa TE, Napoli JA. Isolated penile lymphedema in an adolescent male: a case of metastatic Crohn's disease. *J Pediatr Urol.* 2012;8(5):e55–8.
44. Streight KL, Braun TL, Lowe N, Kim SJ. A rare clinical presentation of metastatic Crohn's disease. *Cureus.* 2020;12(5): e8285.
45. Vint R, Husain E, Hussain F, McClinton S, Ormerod A. Metastatic Crohn's disease of the penis: two cases. *Int Urol Nephrol.* 2012;44(1):45–9.
46. Wylomanski S, Bouquin R, Dréno B, Quéreux G. Spectacular response of metastatic vulval Crohn's disease to infliximab treatment. *Int J Dermatol.* 2016;55(10):1146–8.
47. Gontijo JRV, Leidenz FAB, de Sousa MSLA. Case for diagnosis. Metastatic Crohn's disease. *An Bras Dermatol.* 2016;91(4):531–3.
48. Her Y, Park SE, Kim SS, Kim CW. Metastatic cutaneous Crohn's disease in a child. *Eur J Dermatol.* 2015;25(1):74–5.
49. Amarapurkar DN, Sonavane A, Amarapurkar AD. Metastatic Crohn's Disease. *J Assoc Phys India.* 2017;65(4):86–8.
50. Alotaibi HM, Fathaddin AA, AlMutairi HM, Barakeh MM. Metastatic Crohn's disease in external genitalia with good outcome on adalimumab: a rare case of a Saudi female and a short review. *Cureus.* 2023;15(8): e43380.
51. Bhojryl B, Lyon C. Crohn's disease of the vulva: a prospective study. *J Gastroenterol Hepatol.* 2018;33(12):1969–74.
52. Chatterjee D, Bhattacharjee R, Khullar G, Kumaran S, De D, Saikia UN, et al. Metastatic Crohn disease: a clinicohistological appraisal from a tertiary care center in India. *Am J Dermatopathol.* 2020;42(7):506–12.
53. Costa Blasco M, McFeely O, Doyle C, Wolinska A, Andrawis M, Murphy L, et al. Metastatic Crohn disease improving with vedolizumab. *Br J Dermatol.* 2023;189(2): e35.
54. Das D, Gupta B, Saha M. Metastatic vulvar Crohn's disease—a rare case report and short review of literature. *Indian J Dermatol.* 2016;61(1):70–4.
55. Dederichs F, Ilesalniks I, Sladek M, Tzivinikos C, Hansen R, Muñoz C, et al. Genital granulomatosis in male and female patients with Crohn's disease: clinical presentation and treatment outcomes. *J Crohns Colitis.* 2018;12(2):197–203.
56. Ferreira de Castro L, Gomes R, Sá DC, Fernandes E, Lima R, Tavares M. Metastatic Crohn's disease in paediatrics: Vulvar lesions as the first clinical presentation. *J Paediatr Child Health.* 2023;59(9):1092–4.
57. García-Delgado R, Escario-Travesedo E, Sánchez-Romero A. Absorción sistémica de tacrolimus tópico en enfermedad de Crohn metastásica con úlceras cutáneas. *Actas Dermosifiliogr.* 2016;107(10):866–7.
58. Pampín A, Gamó R, Andreu-Barasoain M, Pinedo F, La Gómez-de FE, López-Estebananz JL. Metastatic Crohn's disease in genital and perianal area preceding 11 years intestinal Crohn's disease. *Int J Dermatol.* 2014;53(3):e176–7.
59. Pereira AS, Coutinho I. A challenging case of metastatic Crohn's disease without gastrointestinal manifestations. *Cureus.* 2023;15(9): e45791.
60. Raman LG, AbdullGaffar B. Metastatic Crohn disease revealing vascular embolization: report of two cases. *J Cutan Pathol.* 2023;50(11):929–32.
61. Shields BE, Richardson C, Arkin L, Kornik R. Vulvar Crohn disease: diagnostic challenges and approach to therapy. *Int J Womens Dermatol.* 2020;6(5):390–4.
62. Xiao TL, Ezenwa E, Ruiz de Luzuriaga A, Hoffman MD. Refractory metastatic Crohn's disease responsive to ustekinumab dose intensification. *JAAD Case Rep.* 2023;32:65–7.
63. Woody MM, Holliday AC, Gavino ACP, McReynolds A, Soldano AC. Metastatic vulvovaginal Crohn disease in the setting of well-controlled intestinal disease. *Cutis.* 2018;102(2):E16–8.

Publisher's Note

Springer Nature remains neutral with regard to jurisdictional claims in published maps and institutional affiliations.