

CASE REPORT

Open Access



Acute respiratory distress syndrome following administration of gadolinium contrast agent: a case report

Eduardo Atsushi Osawa^{1,2}, Juliana Fernandez Fernandes Kleiman² and Alexandre Toledo Maciel^{1,2*} 

Abstract

Background: Gadolinium-based contrast agents are used extensively in magnetic resonance imaging to assist diagnosis of medical conditions. Despite their documented safety profile, severe adverse events do occur, and their documentation may serve to raise the awareness of the medical community.

Case presentation: We report the case of a 15-year-old white Latin American female patient admitted to the intensive care unit for acute respiratory distress syndrome following administration of gadolinium. She did not have rash or tongue swelling but developed hypotension responsive to fluid administration and severe hypoxemia. Chest computed tomography revealed bilateral pulmonary compromise with multiple confluent consolidations. She received methylprednisolone and noninvasive ventilatory support including bilevel positive airway pressure ventilation and high-flow nasal cannula, and underwent a rapid recovery.

Conclusion: Gadolinium-based contrast agent-induced acute respiratory distress syndrome, albeit rare, should be included in the differential diagnosis of respiratory failure shortly after magnetic resonance imaging, which is nowadays a frequent diagnostic procedure, potentially increasing the awareness of this serious complication.

Keywords: Gadolinium, Acute respiratory distress syndrome, Anaphylaxis

Introduction

Gadolinium-based contrast agents (GBCAs) are employed widely in magnetic resonance imaging (MRI) to assist the diagnosis and follow-up of numerous medical conditions. It is estimated that 50 million doses are injected annually, and side effects are rarely reported [1]. Despite extensive documentation on the safety profile of GBCAs, severe adverse events occur and may serve to raise the awareness of the medical community. A rare but serious adverse event related to GBCA administration is the development of acute respiratory distress syndrome (ARDS), which is a life-threatening, extensive, and

diffuse inflammatory process of the lungs with damage of the alveolocapillary barrier leading to noncardiogenic pulmonary edema, gas exchange impairment, and severe hypoxemia [1]. In this case, ARDS was the terminal complication of GBCA administration rather than the primary event. Thus, we present this case of a patient who developed ARDS after GBCA administration.

Case presentation

A 15-year-old white Latin American female patient underwent contrast magnetic resonance imaging (MRI) for outpatient investigation of persistent pelvic pain. In a recent emergency department (ED) visit for the same complaint, a normal urinalysis was obtained. Her past medical history was unremarkable, and she did not take any medications and denied alcohol, tobacco, or any drug abuse. Few minutes after receiving gadolinium

*Correspondence: alexandre.toledo@imedgroup.com.br

¹Imed Group Research Department, Av. Angélica, 2.530 - 9º andar, São Paulo, SP 01228-200, Brazil

Full list of author information is available at the end of the article



© The Author(s) 2022. **Open Access** This article is licensed under a Creative Commons Attribution 4.0 International License, which permits use, sharing, adaptation, distribution and reproduction in any medium or format, as long as you give appropriate credit to the original author(s) and the source, provide a link to the Creative Commons licence, and indicate if changes were made. The images or other third party material in this article are included in the article's Creative Commons licence, unless indicated otherwise in a credit line to the material. If material is not included in the article's Creative Commons licence and your intended use is not permitted by statutory regulation or exceeds the permitted use, you will need to obtain permission directly from the copyright holder. To view a copy of this licence, visit <http://creativecommons.org/licenses/by/4.0/>. The Creative Commons Public Domain Dedication waiver (<http://creativecommons.org/publicdomain/zero/1.0/>) applies to the data made available in this article, unless otherwise stated in a credit line to the data.

during MRI, she presented to the ED with shortness of breath, chest pain, dizziness, nausea, and vomiting. Upon admission, she had a brief period of loss of consciousness and her vital signs were as follows: blood pressure (BP), 84/40 mmHg; temperature, 36.4 °C; heart rate (HR), 122 beats per minute; respiratory rate (RR), 30 breaths per minute, and peripheral oxygen saturation (SpO₂) of 78%. Her pulmonary auscultation revealed bilateral rales, but she did not have rash, or tongue or lip swelling. Despite significant hypoxemia, she was able to speak in whole sentences, and inhaled oxygen was delivered through a non-rebreather mask (NRBM) at 10 L per minute. She immediately received 500 mg of hydrocortisone and a 1 L bolus of intravenous crystalloids, but epinephrine was not administered upon the patient's presentation. Also, antimicrobial therapy with ceftriaxone and azithromycin was initiated.

Laboratory tests demonstrated a hemoglobin level of 18.6 g/dL, a slightly elevated white blood cell count (15,360/mm³, normal 4000–11,000/mm³), an increased C-reactive protein (CRP) concentration (41.8 mg/L, normal: <0.5 mg/L), a lactate dehydrogenase (LDH) level of 176 U/L (normal 135–214 U/L), and a D-dimer concentration of 1.7 mg/mL (normal:<0.5 mg/mL). B-type natriuretic peptide and troponin levels were low, and the echocardiogram was normal.

A chest computed tomography (CT) was performed around 1 hour after GBCA administration and showed bilateral pulmonary compromise secondary to multiple confluent consolidations located mainly in the posterior aspects of the lower lobes. There were also regions of ground-glass opacities that were more evident in the upper lobes along with diffuse thickening of interalveolar septa (Fig. 1). A CT pulmonary angiography ruled out the diagnosis of pulmonary embolism. A severe acute respiratory syndrome coronavirus 2 (SARS-CoV-2) nasopharyngeal swab testing came back negative.

She was then transferred to the intensive care unit (ICU) with improved vital signs: BP, 119/71 mmHg, HR, 122 beats per minute, and SpO₂ of 93%. Due to high oxygen requirement, methylprednisolone 1 mg/kg was prescribed and she was commenced on bilevel positive airway pressure (BiPAP) ventilation and high-flow nasal cannula (HFNC). The patient showed substantial improvement over the following 12 hours, which enabled her to be weaned off noninvasive ventilatory support. She was afebrile during the entire hospital stay. She was discharged from ICU on day 2 receiving inhaled oxygen via nasal cannula at 1 L per minute and discharged home on day 3, with SpO₂ of 98% on room air. Owing to the patient's rapid recovery after supportive treatment and the absence of clinical evidence of infection, the decision to cease antibiotic therapy was made. Corticosteroid

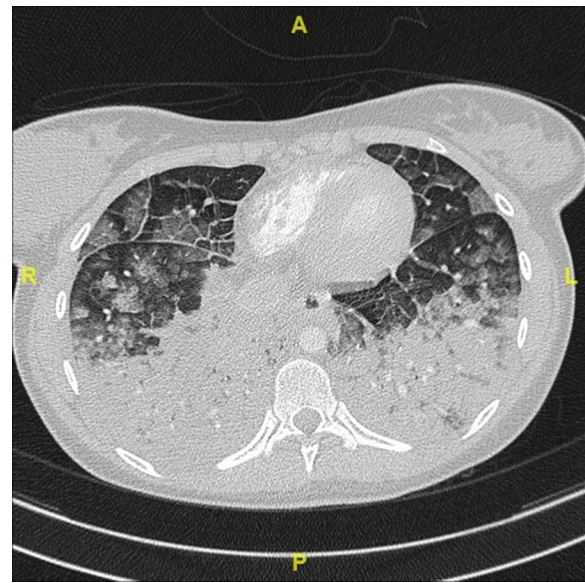


Fig. 1 Chest computed tomography (CT) showing bilateral multiple confluent consolidations located mainly in the posterior aspects of the lower lobes associated with regions of ground-glass opacities in the upper lobes and diffuse thickening of interalveolar septa

treatment was tapered down slowly over 30 days after discharge. Six months after initial presentation, the patient remained well and the follow-up was uneventful.

Discussion

We report the case of a young female patient who developed a life-threatening complication after GBCA administration. This case is unique as respiratory distress and hypotension occurred immediately after infusion, there was no skin involvement, and the symptoms improved rapidly with noninvasive supportive therapies.

The advance of imaging technology in recent decades has led to a substantial increase in GBCA use. It is estimated that 50 million doses are injected annually, and side effects are rarely reported [2]. As compared with iodine-based contrast agents, GBCAs are associated with a lower incidence of acute reactions [3] and guidelines on their safe use have primarily focused on the risks for renal toxicity and development of nephrogenic systemic fibrosis [4]. GBCA-associated adverse events can be classified into two categories: nonallergic reactions (headache, dizziness, nausea, vomiting, pain at the injection site) and idiosyncratic allergy-like reactions [5]. Despite growing awareness of GBCA-related complications owing to increased MRI use, severe life-threatening reactions are rare and were reported to range from 0.1% to 0.001% [6, 7].

Drug-induced acute lung injury is a challenging diagnosis in clinical practice. There is no specific biomarker for ARDS triggered by GBCA, and the clinical presentation is indistinguishable from other causes. Therefore, the etiology is suspected by the temporal relationship between drug injection and development of symptoms, along with the exclusion of other risk factors. The pathogenesis is unknown; however, explanatory mechanisms have not been linked to systemic anaphylaxis but to chemical endothelial injury triggered by activation of the complement system [8]. This results in the exudative phase of ARDS characterized by accumulation of protein-rich fluid within the interstitium and alveolus [1, 9].

We identified 11 cases of ARDS associated with GBCA administration reported in literature. In contrast to our patient, fever was reported by some investigators [10–12] and was deemed to be a feature of the ARDS presentation. Patients differed with regard to disease severity, with supportive respiratory support varying from noninvasive therapies [10–14] to invasive mechanical ventilation [15–18] and venoarterial extracorporeal membrane oxygenation (VA-ECMO) [19]. In two patients [17, 19], cardiac arrest was documented, but they recovered after cardiopulmonary resuscitation (CPR) and supportive therapies. Notably, in our patient, we used a noninvasive respiratory support strategy identical to that described by Nguyen [12] comprising noninvasive ventilation (NIV) and high-flow nasal cannula (HFNC), with a similar outcome. Interestingly, aside from the similarities that this patient presented with our case, including age group, gender, and reason for MRI, they also had hemoconcentration upon ED arrival. This finding may be associated with fluid extravasation into the interstitium and alveoli, and in both cases, hemoglobin levels normalized after clinical improvement.

In only two patients [10, 17], the onset of symptoms occurred immediately after contrast administration, a finding similar to our case report. In other patients, the duration from GBCA injection and symptom onset ranged from 10 minutes to 3 hours. In a study comprising six prospective observational multicenter studies, 82.4% of patients developed acute drug reactions within 5 minutes after GBCA administration, and the majority of the study population did so within 15 minutes [7]. In fact, despite the absence of skin involvement, our patient fulfilled the diagnostic criteria for anaphylaxis [20] given the presentation of hypotension and respiratory distress following contrast administration. Measurement of trypsin levels could have assisted in the differential diagnosis, however we were unable to obtain this during hospitalization. As in other cases, our patient received supportive therapies and a course of corticosteroid treatment. She showed rapid clinical improvement without requiring either vasopressor therapy

or advanced respiratory support modalities. Because sepsis is the major cause of ARDS, antibiotics were administered initially, but unfortunately no blood cultures were obtained. Urinalysis was normal in a recent ED admission, fever and shivering were absent, and a modest CRP increment was observed. Moreover, the absence of signs of sepsis or respiratory failure before gadolinium administration and the temporal relationship between GBCA infusion and symptom onset suggest that ARDS was not triggered by infection.

Conclusion

GBCA-induced ARDS is a rare but potentially serious complication and should be included in the differential diagnosis for respiratory failure shortly after MRI. Since gadolinium use is very frequent in the current medical diagnostic armamentarium, this adverse event is expected to be more frequently observed. No specific treatment has been advocated, and supportive therapy seems to be the cornerstone for these cases. Methylprednisolone may eventually be useful, but its real utility remains to be defined.

Acknowledgements

None.

Author contributions

JK conceived the idea for this case report and took care of the patient, EO carried out the literature review on the subject and, together with AM, wrote the manuscript. All authors read and approved the final manuscript.

Funding

The authors did not receive support from any organization for the submitted work.

Availability of data and materials

The data used to support the findings of this case study are included within the article.

Declarations

Ethics approval and consent to participate

Ethics approval was waived due to the retrospective and observational nature of the publication as well as no identification of the patient in the text or in the figure.

Consent for publication

Written informed consent was obtained from the patient's legal guardian for publication of this case report and any accompanying images. A copy of the written consent is available for review by the Editor-in-Chief of this journal.

Competing interests

The authors declare that there are no conflicts of interest.

Author details

¹Imed Group Research Department, Av. Angélica, 2.530 - 9º andar, São Paulo, SP 01228-200, Brazil. ²Adult Intensive Care Unit, São Camilo Hospital, Pompeia Unit. Av. Pompéia, 1178, São Paulo, SP 05022-001, Brazil.

Received: 8 August 2022 Accepted: 11 October 2022

Published online: 17 November 2022

References

1. Thompson BT, Chambers RC, Liu KD. Acute respiratory distress syndrome. *N Engl J Med*. 2017;377(6):562–72.
2. McDonald JS, Hunt CH, Kolbe AB, Schmitz JJ, Hartman RP, Maddox DE, et al. Acute adverse events following gadolinium-based contrast agent administration: a single-center retrospective study of 281 945 injections. *Radiology*. 2019;292(3):620–7.
3. Herborn CU, Honold E, Wolf M, Kemper J, Kinner S, Adam G, et al. Clinical safety and diagnostic value of the gadolinium chelate gadoterate meglumine (Gd-DOTA). *Invest Radiol*. 2007;42(1):58–62.
4. Weinreb JC, Rodby RA, Yee J, Wang CL, Fine D, McDonald RJ, et al. Use of intravenous gadolinium-based contrast media in patients with kidney disease: consensus statements from the American College of Radiology and the National Kidney Foundation. *Radiology*. 2021;298(1):28–35.
5. Granata V, Cascella M, Fusco R, dell'Aprovola N, Catalano O, Filice S, et al. Immediate adverse reactions to gadolinium-based MR contrast media: a retrospective analysis on 10,608 examinations. *Biomed Res Int*. 2016;2016:3918292.
6. Murphy KP, Szopinski KT, Cohan RH, Mermillod B, Ellis JH. Occurrence of adverse reactions to gadolinium-based contrast material and management of patients at increased risk: a survey of the American Society of Neuroradiology Fellowship Directors. *Acad Radiol*. 1999;6(11):656–64.
7. Forsting M, Palkowitsch P. Prevalence of acute adverse reactions to gadobutrol—a highly concentrated macrocyclic gadolinium chelate: review of 14,299 patients from observational trials. *Eur J Radiol*. 2010;74(3):e186–92.
8. Lee-Chiong T Jr, Matthay RA. Drug-induced pulmonary edema and acute respiratory distress syndrome. *Clin Chest Med*. 2004;25(1):95–104.
9. Bakowitz M, Bruns B, McCunn M. Acute lung injury and the acute respiratory distress syndrome in the injured patient. *Scand J Trauma Resusc Emerg Med*. 2012;20:54.
10. Gupta N, Davidson J, Li A. Acute respiratory distress syndrome due to gadolinium administration. *J Intensive Care Soc*. 2013;14(2):159–62.
11. Kerget B, Aksakal A, Afsin DE, Araz O, Ucar EY, Akgun M, et al. Acute respiratory distress syndrome after the use of gadolinium contrast agent. *Respir Med Case Rep*. 2018;25:336–8.
12. Nguyen C, Pham T. Non-cardiogenic pulmonary oedema following the use of gadolinium-based contrast medium: a case report. *J Crit Care Med (Targu Mures)*. 2020;6(3):181–5.
13. Lee Y, Chung TY, Liu HC. A rare case of acute respiratory distress syndrome caused by use of gadolinium-based magnetic resonance imaging contrast media. *Respirol Case Rep*. 2019;7(8):e00483.
14. Lucas A, Mohan G, Winkler A, Gardner K, Whalen M. Acute lung injury following gadolinium contrast: a case report. *J Emerg Crit Care Med*. 2021;5(18):1–6.
15. Acharya S, Anwar S, Madala S, Thapa S, Maroun R. Delayed anaphylaxis due to gadolinium—a rare clinical scenario. *Radiol Case Rep*. 2021;16(9):2522–5.
16. Kato K, Fujimoto S, Inukai S, Takatsu H, Kono Y, Kasai K. Late-onset acute respiratory distress syndrome induced by a gadolinium-based contrast agent. *Respir Med Case Rep*. 2020;29:100990.
17. Demirhan A, Yasar Tekelioglu U, Akkaya A, Dagistan E, Suzi Ayhan S, Ozturk S, et al. Magnetic resonance imaging contrast agent related pulmonary edema: a case report. *Eur Rev Med Pharmacol Sci*. 2012;16(Suppl 4):110–2.
18. Park J, Byun IH, Park KH, Lee JH, Nam EJ, Park JW. Acute respiratory distress syndrome after the use of gadolinium contrast media. *Yonsei Med J*. 2015;56(4):1155–7.
19. Guru PK, Bohman JK, Fleming CJ, Tan HL, Sanghavi DK, De Moraes AG, et al. Severe acute cardiopulmonary failure related to gadobutrol magnetic resonance imaging contrast reaction: successful resuscitation with extracorporeal membrane oxygenation. *Mayo Clin Proc*. 2016;91(3):362–6.
20. Cardona V, Ansotegui IJ, Ebisawa M, El-Gamal Y, Fernandez Rivas M, Fineman S, et al. World Allergy Organization anaphylaxis guidance 2020. *World Allergy Organ J*. 2020;13(10):100472.

Publisher's Note

Springer Nature remains neutral with regard to jurisdictional claims in published maps and institutional affiliations.

Ready to submit your research? Choose BMC and benefit from:

- fast, convenient online submission
- thorough peer review by experienced researchers in your field
- rapid publication on acceptance
- support for research data, including large and complex data types
- gold Open Access which fosters wider collaboration and increased citations
- maximum visibility for your research: over 100M website views per year

At BMC, research is always in progress.

Learn more biomedcentral.com/submissions

