

CASE REPORT

Open Access



Delayed pharyngocutaneous fistula caused by molecular targeted therapy: a case report

Mioko Matsuo*, Kazuki Hashimoto, Rina Jiromaru and Takashi Nakagawa

Abstract

Background: Molecular-targeted agents used as a treatment for cancer can cause some rare and serious adverse events such as, delayed wound healing. Depending on the anticancer drug used, temporary withdrawal may be recommended before and after surgery to avoid complications. Once a surgical incision has healed and closed completely, wounds rarely open because of the initiation of molecular targeted therapy several months to years after surgery. Here, we aimed to describe a rare complication of pharyngocutaneous fistula in two patients that was thought to be caused by molecular targeted therapy.

Case presentation: Case 1 involved a 64-year-old asian man who developed a delayed pharyngocutaneous fistula 3 months after total laryngectomy for laryngeal cancer. Ramucirumab, a vascular endothelial growth factor receptor inhibitor used for recurrent gastric cancer, was speculated to be involved. Case 2 involved a 71-year-old japanese man who developed a delayed pharyngocutaneous fistula 2 years and 1 month after total pharyngeal laryngectomy for pharyngeal cancer. It was speculated that imatinib, a platelet-derived growth factor receptor alpha inhibitor used for chronic myeloid leukemia, was involved.

Conclusions: Although the incidence of late drug-induced anastomotic leakage is very low, when it occurs, it makes oral intake impossible for an extended period and interferes with the appropriate cancer treatment. In this report, we demonstrate the details of these two patients with such a rare complication, which may help accumulate essential data on this topic.

Keywords: Molecular targeted therapy, Delayed pharyngocutaneous fistula, Anastomotic leakage, Adverse events

Background

In recent years, cancer research has progressed significantly at the molecular level. Specifically, the development and clinical introduction of molecular-targeted agents directed at certain molecular mechanisms have been rapidly advancing. The development of molecular targeted therapy has contributed to prolonged survival of patients with several malignancies [1, 2]. In contrast, various adverse events peculiar to molecular-targeted agents, which are different from conventional cytotoxic

anticancer agents, have been identified. For example, rashes and hand-foot syndrome are frequent adverse events, with an incidence of $\geq 80\%$ characteristic of cetuximab and sorafenib, respectively [3]. In addition, although the incidence is less frequent, serious adverse events, with an incidence of approximately 1.5–2%, such as gefitinib-related interstitial lung disease [4] and trastuzumab-associated cardiac dysfunction [5], require attention and awareness.

Delayed wound healing is also a rare but severe and life-threatening adverse event caused by molecular-targeted agents [6, 7]. Normally, when tissue is damaged, various wound healing factors are released to promote cell growth and angiogenesis, thereby regenerating the damaged tissue. Vascular endothelial growth factor

*Correspondence: miolovemio@hotmail.co.jp

Department of Otorhinolaryngology, Graduate School of Medical Sciences, Kyushu University, 3-1-1 Maidashi, Higashi-ku, Fukuoka-City, Fukuoka Prefecture 812-8582, Japan



© The Author(s) 2022. **Open Access** This article is licensed under a Creative Commons Attribution 4.0 International License, which permits use, sharing, adaptation, distribution and reproduction in any medium or format, as long as you give appropriate credit to the original author(s) and the source, provide a link to the Creative Commons licence, and indicate if changes were made. The images or other third party material in this article are included in the article's Creative Commons licence, unless indicated otherwise in a credit line to the material. If material is not included in the article's Creative Commons licence and your intended use is not permitted by statutory regulation or exceeds the permitted use, you will need to obtain permission directly from the copyright holder. To view a copy of this licence, visit <http://creativecommons.org/licenses/by/4.0/>. The Creative Commons Public Domain Dedication waiver (<http://creativecommons.org/publicdomain/zero/1.0/>) applies to the data made available in this article, unless otherwise stated in a credit line to the data.

(VEGF) and platelet-derived growth factor (PDGF) are key factors that play important roles in the wound healing process [8, 9]. Therefore, delayed wound healing may occur if these factors are inhibited. In fact, the administration of bevacizumab, a VEGF inhibitor, induces adverse events, such as anastomotic leak and fistula formation, resulting in delayed wound healing [10, 11]. The incidence of such adverse events is low, approximately 1–2% [10]. However, because these adverse events may cause serious consequences, the causative drug should be withdrawn 6–8 weeks before and after surgery [6, 7, 11].

A few articles have reported molecular-targeted agent-induced diastasis of a surgical wound that healed and completely closed months to years after the surgery [12–14]. Here, we report two cases of delayed pharyngeal cutaneous fistula considered to be caused by molecular targeted therapy.

Case presentation

Case 1

A 64-year-old asian man received cisplatin/5-fluorouracil (FU) combined with radiotherapy (60 Gy, 23 fractions) for esophageal cancer in 2014. In January 2018, he received 70 Gy (35 fractions) chemoradiotherapy with cisplatin for laryngeal cancer. In June 2018, the patient underwent total gastrectomy and postoperative adjuvant chemotherapy (capecitabine/oxaliplatin) for gastric cancer. In October 2018, total laryngectomy was performed for laryngeal cancer recurrence. There was no postoperative wound issue, oral ingestion was started 1 week after the operation, and the wound progressed uneventfully. Subsequently, gastric cancer recurred in November 2018, and combination therapy with ramucirumab and paclitaxel was initiated. In January 2019 (3 months after the previous surgery), the total laryngectomy skin incision suddenly started

to leak saliva without any warning signs, such as redness, abscess formation, or skin ulceration (Fig. 1a). A delayed pharyngocutaneous fistula, which appeared 3 months after total laryngectomy, was diagnosed. Although ramucirumab was discontinued because the adverse event was thought to be caused by the drug, the fistula continued to increase in size (Fig. 1b). It was managed with various conservative treatments, for example, antibiotics, discontinuation of oral intake, enteral feeding, and negative pressure wound therapy. In February 2019 (1 month after the development of the fistula), the fistula was closed using pectoral major musculocutaneous flap reconstructive surgery. However, shortly after the operation, a new fistula appeared at a site different from the previous fistula. The new fistula was again treated with the same conservative approach. This conservative treatment was performed for approximately 7 months repeatedly for new fistulas, and a second pectoral major musculocutaneous flap reconstructive surgery was performed in August 2019 (7 months after the development of the first fistula). There was no subsequent fistula relapse, but it took 8 months from the appearance of the first fistula to complete closure (Fig. 1c). For 8 months, he was unable to orally ingest much of anything, nor could he receive chemotherapy for stomach cancer. In this patient, ramucirumab was administered for 2 months before the first surgery for recurrence of gastric cancer, and a pharyngocutaneous fistula developed 3 months after the total laryngectomy. The fistula was intractable, and complete closure was achieved after 8 months. Anemia, hypoalbuminemia, underweight, and hypothyroidism were detected in the laboratory data (Table 1). However, considering the late onset of 3 months after surgery, this case was judged to be a complication of ramucirumab, a VEGF receptor (VEGFR) inhibitor.

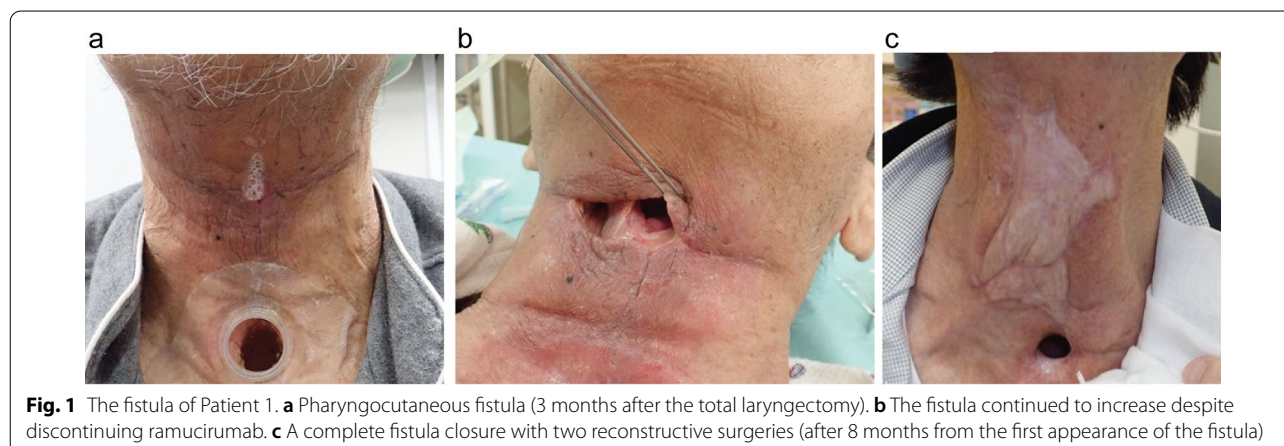


Table 1 Laboratory data at the time of fistula formation in the two cases

	Normal range	Patient 1	Patient 2
White blood cell (/ μ L)	3300–8600	6630	7080
Hemoglobin (g/dL)	13.7–16.8	10.0	12.5
Platelet (10^3 / μ L)	158–348	357	218
Total protein (g/dL)	6.6–8.1	6.1	6.9
Albumin (g/dL)	4.1–5.1	3.2	4.0
Fasting blood glucose (mg/dL)	73–109	75	108
HbA1c (%)	4.9–6.0	5.1	5.8
CRP (mg/dL)	0.61–4.23	1.8	0.10
TSH (mIU/L)	0.61–4.23	6.57	4.18
F-T4 (ng/dL)	0.7–1.48	1.02	0.98
Factor XIII (%)	70–140	100	N.A.
BMI (kg/m^2)	18.5–25	16.5	21.0

* *HbA1c* glycated hemoglobin, *CRP* C-reactive protein, *TSH* thyroid-stimulating hormone, *BMI* body mass index [range according to the World Health Organization (WHO) Asian-BMI classification], *N.A.* not available

Case 2

A 71-year-old Japanese man underwent subtotal tongue resection, cervical dissection, and flap reconstruction for oral cancer in March 2014. In April 2019, partial pharyngeal resection, total laryngectomy, cervical dissection, and flap reconstruction were performed for laryngeal cancer. Oral ingestion was initiated 1 week after the operation, and the procedure was continued without any wound complications. He later developed chronic myelogenous leukemia, and imatinib was administered in January 2021. In May 2021 (2 years and 1 month after the previous surgery), the total laryngectomy skin incision suddenly started leaking saliva without any symptoms, such as redness, abscess formation, or skin ulceration (Fig. 2a). This was judged to be a delayed pharyngocutaneous fistula that appeared more than 2 years after total laryngectomy. Even after discontinuation of imatinib, the

fistula continued to increase in size for 1 week (Fig. 2b), but it began to shrink 10 days after the drug was discontinued. The fistula closed 2 months after negative pressure wound therapy (Fig. 2c). In this patient, imatinib was administered for 2 months before surgery for chronic myelogenous leukemia. The pharyngocutaneous fistula showed delayed onset 2 years after the total laryngectomy. Mild anemia was detected in his laboratory data (Table 1). Consequently, the case was judged to be a complication of treatment with imatinib, a PDGF receptor (PDGFR) inhibitor.

Discussion and conclusions

Pharyngocutaneous fistula is one of the major complications after laryngectomy [15–17], and the reported frequency of fistula ranges from 7.4% to 58.0% [15, 16]. However, the fistula typically occurs a median of 9–20 (range: 2–28) days after surgery [16, 18]; thus, a pharyngocutaneous fistula that develops more than several months after surgery is extremely rare. In the usual occurrence of pharyngocutaneous fistulas, which develop in approximately 9–20 days, a metaanalysis indicated that prior radiation therapy exposure [15, 17], anemia [15, 17], positive surgical margin [15, 17], supraglottic subsite or hypopharyngeal tumor site [15, 17], and chronic obstructive pulmonary disease [17] have been reported as risk factors. Meanwhile, only one case of fistula that developed a long time after the operation, similar to in our cases, has been reported to date [13]. As mentioned above, in an unusual case of delayed fistula formation, it is difficult to apply the same risk factors involved in a normal pharyngocutaneous fistula formation. Therefore, in the present cases, a strong role

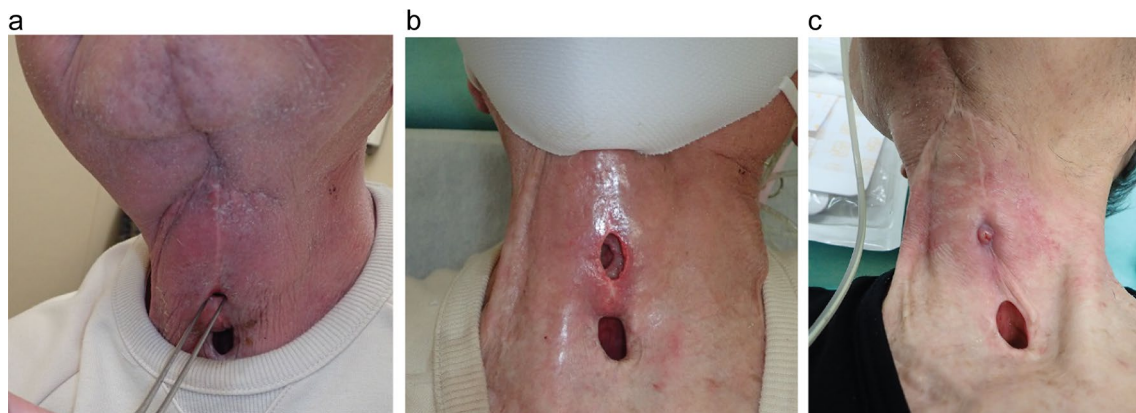


Fig. 2 The fistula of Patient 2. **a** Pharyngocutaneous fistula (2 years and 1 month after the previous surgery). **b** The fistula continued to increase despite discontinuing imatinib. **c** Complete closure of the fistula with conservative treatment by negative pressure wound therapy (2 months from the first appearance of the fistula)

of VEGF and PDGF inhibitors was considered in inhibiting wound healing.

When using molecular-targeted drugs that block signaling pathways related to VEGF and PDGF, which are essential for wound healing, the risk of wound complications must be considered. Drug suspension is recommended for approximately 2 weeks to 2 months before and after surgery, depending on the half-life of each drug, to avoid the risk of wound-related complications [6]. Wound healing may be difficult to achieve after surgery in patients who have already been administered this type of molecular targeting agent. In such cases, the risk of delayed wound healing can be assumed in advance, and surgery can be planned after a safe withdrawal period, thereby reducing the incidence of wound reopening [11]. Conversely, in patients who were administered the agent after surgery, healed wounds may reopen because of drug administration.

However, as shown in the present cases, it is rare and difficult to predict the development of delayed-onset wound reopening due to a molecular-targeted drug in patients who underwent surgery months to years ago with complete closure of the surgical wound, even if the drug is associated with a risk of wound healing complications. Rare cases of delayed wound dehiscence caused by molecular-targeted drugs have been reported. Anastomotic leakage resulting from bevacizumab administration 33 months after surgery for colorectal cancer has been reported previously [12]. A pharyngocutaneous fistula was reported to have developed 23 years after administration of cabozantinib after total pharyngeal-laryngeal esophagectomy [13]. In addition, the formation of a large deep ulcer was reported after imatinib administration in a patient with skin wounds, 4 years after the wounds healed [14].

Ramucirumab, the drug used in the first case, is a monoclonal antibody that binds to VEGFR and is used to treat recurrent gastric and colon cancers. A rare incidence of adverse events (1–2%) has been reported after ramucirumab administration, including delayed wound healing and fistula formation [19, 20]. Imatinib, which is an inhibitor of PDGFR and is used for the treatment of chronic myeloid leukemia, was used in the second case. A high incidence of skin disorders (edema and rash) because of imatinib administration has been reported [21], but no reports on delayed wound healing or fistula formation incidence have been published. Imatinib has been shown to be effective in keloid scar treatment because it reduces fibroblasts and collagen formation [22]. It was speculated that imatinib use might result in delayed wound reopening because of the reduced number of fibroblasts and collagen in the wound.

Cancer cure rates have improved with the development of anticancer drugs, and the number of cancer survivors continues to increase. As a result of prolonged survival, the probability of suffering from multiple cancers in a lifetime and receiving various cancer treatments has also increased. In addition, in recent years, cancer treatment strategies have become more complicated because of the dramatically increased use of anticancer drug therapy. Adverse events associated with these treatments have also been complicated, and a new range of unexpected complications has been reported.

Anticancer drug therapy is administered along with measures against various adverse events. However, it may be possible to start anticancer drugs, such as VEGFR or PDGFR, for the treatment of new cancers different from the previous cancer treated by surgical therapy several months to years ago. In such cases, there is a concern that the drugs may be administered without evaluating the risk to the wound from the previous surgery. Although rare, anastomotic leakage makes oral intake impossible for an extended period and interferes with appropriate cancer treatment. The two cases in this report were drug-induced delayed-onset pharyngocutaneous fistulas. Detailed information on this very rare complication must be elucidated to appropriately increase awareness among healthcare professionals involved in cancer treatment.

In conclusion, drug-induced late-onset pharyngocutaneous fistula is rare. However, when it occurs, it significantly lowers the patients' quality of life and is difficult to treat. Thus, it is indispensable to accumulate more data on such rare cases, and we believe that this report offers more insights into drug-induced late-onset pharyngocutaneous fistula.

Abbreviations

VEGF: Vascular endothelial growth factor; PDGF: Platelet-derived growth factor; VEGFR: VEGF receptor; PDGFR: PDGF receptor.

Acknowledgements

The authors would like to thank Editage (www.editage.com) for their English language review.

Author contributions

MM was a major contributor in writing the manuscript. KH and RJ were the primary physicians involved in patient care. TN supervised the preparation of this manuscript. All authors read and approved the final manuscript.

Funding

The authors did not receive any financial support.

Availability of data and materials

Data sharing is not applicable to this manuscript as no datasets were generated.

Declarations

Ethics approval and consent to participate

This report was approved by the Institutional Ethics Review Board of Kyushu University (No. 29-43.) and performed in accordance with the principles of the Declaration of Helsinki. Patients provided written informed consent for the report.

Consent for publication

Written informed consent was obtained from the patient for publication of this case report and the accompanying images. A copy of the written consent is available for review by the Editor-in-Chief of this journal.

Competing interests

The authors declare that they have no competing interests.

Received: 12 May 2022 Accepted: 21 September 2022

Published online: 22 October 2022

References

- Bedard PL, Hyman DM, Davids MS, Siu LL. Small molecules, big impact: 20 years of targeted therapy in oncology. *Lancet*. 2020;395:1078–88. [https://doi.org/10.1016/S0140-6736\(20\)30164-1](https://doi.org/10.1016/S0140-6736(20)30164-1).
- Lee YT, Tan YJ, Oon CE. Molecular targeted therapy: treating cancer with specificity. *Eur J Pharmacol*. 2018;834:188–96. <https://doi.org/10.1016/j.ejphar.2018.07.034>.
- Curry JL, Torres-Cabala CA, Kim KB, Tetzlaff MT, Duvic M, Tsai KY, et al. Dermatologic toxicities to targeted cancer therapy: shared clinical and histologic adverse skin reactions. *Int J Dermatol*. 2014;53:376–84. <https://doi.org/10.1111/ijd.12205>.
- Shi L, Tang J, Tong L, Liu Z. Risk of interstitial lung disease with gefitinib and erlotinib in advanced non-small cell lung cancer: a systematic review and meta-analysis of clinical trials. *Lung Cancer*. 2014;83:231–9. <https://doi.org/10.1016/j.lungcan.2013.11.016>.
- Yeh ET, Bickford CL. Cardiovascular complications of cancer therapy: incidence, pathogenesis, diagnosis, and management. *J Am Coll Cardiol*. 2009;53:2231–47. <https://doi.org/10.1016/j.jacc.2009.02.050>.
- Chen HX, Cleck JN. Adverse effects of anticancer agents that target the VEGF pathway. *Nat Rev Clin Oncol*. 2009;6:465–77. <https://doi.org/10.1038/nrclinonc.2009.94>.
- Bose D, Meric-Bernstam F, Hofstetter W, Reardon DA, Flaherty KT, Ellis LM. Vascular endothelial growth factor targeted therapy in the perioperative setting: implications for patient care. *Lancet Oncol*. 2010;11:373–82. [https://doi.org/10.1016/S1470-2045\(09\)70341-9](https://doi.org/10.1016/S1470-2045(09)70341-9).
- Rajkumar VS, Shiwen X, Bostrom M, Leoni P, Muddle J, Ivarsson M, et al. Platelet-derived growth factor-beta receptor activation is essential for fibroblast and pericyte recruitment during cutaneous wound healing. *Am J Pathol*. 2006;169:2254–65. <https://doi.org/10.2353/ajpath.2006.060196>.
- Bao P, Kodra A, Tomic-Canic M, Golinko MS, Ehrlich HP, Brem H. The role of vascular endothelial growth factor in wound healing. *J Surg Res*. 2009;153:347–58. <https://doi.org/10.1016/j.jss.2008.04.023>.
- Zhang H, Huang Z, Zou X, Liu T (2016) Bevacizumab and wound-healing complications: a systematic review and meta-analysis of randomized controlled trials. *Oncotarget*. 2016;7:82473–81. <https://doi.org/10.18632/oncotarget.12666>
- Scappaticci FA, Fehrenbacher L, Cartwright T, Hainsworth JD, Heim W, Berlin J, et al. Surgical wound healing complications in metastatic colorectal cancer patients treated with bevacizumab. *J Surg Oncol*. 2005;91:173–80. <https://doi.org/10.1002/jso.20301>.
- August DA, Serrano D, Poplin E. "Spontaneous", delayed colon and rectal anastomotic complications associated with bevacizumab therapy. *J Surg Oncol*. 2008;97:180–5. <https://doi.org/10.1002/jso.20938>.
- Ackerman J, Kent S, Walker P. Gastropharyngeal anastomotic leak in medullary thyroid carcinoma following initiation of a tyrosine kinase inhibitor: a case report of an unusual side effect of cabozantinib. *Ann Otol Rhinol Laryngol*. 2020;129:657–61. <https://doi.org/10.1177/0003489420902161>.
- Ronick M, Erfurt-Berge C. Impaired wound healing with imatinib mesylate therapy. *Adv Skin Wound Care*. 2021;34:109–11. <https://doi.org/10.1097/01.ASW.0000725176.48771.0f>.
- Liang JW, Li ZD, Li SC, Fang FQ, Zhao YJ, Li YG. Pharyngocutaneous fistula after total laryngectomy: a systematic review and meta-analysis of risk factors. *Auris Nasus Larynx*. 2015;42:353–9. <https://doi.org/10.1016/j.anl.2015.04.002>.
- Galli J, De Corso ED, Volante M, Almadori G, Paludetti G. Postlaryngectomy pharyngocutaneous fistula: incidence, predisposing factors, and therapy. *Otolaryngol Head Neck Surg*. 2005;133:689–94. <https://doi.org/10.1016/j.otohns.2005.07.025>.
- Dedivitis RA, Aires FT, Cernea CR, Brandão LG. Pharyngocutaneous fistula after total laryngectomy: systematic review of risk factors. *Head Neck*. 2015;37:1691–7. <https://doi.org/10.1002/hed.23804>.
- Saki N, Nikakhlagh S, Kazemi M. Pharyngocutaneous fistula after laryngectomy: incidence, predisposing factors, and outcome. *Arch Iran Med*. 2008;11:314–7. 08113/AIM.0013.
- Sashegyi A, Zhang Y, Lin Y, Binder P, Ferry D. Comment on: risk of gastrointestinal perforation in cancer patients receiving ramucirumab: a meta-analysis of randomized controlled trials. *J Chemother*. 2017;29:62–4. <https://doi.org/10.1080/1120009X.2015.1113023>.
- Arnold D, Fuchs CS, Tabernero J, Ohtsu A, Zhu AX, Garon EB, et al. Meta-analysis of individual patient safety data from six randomized, placebo-controlled trials with the antiangiogenic VEGFR2-binding monoclonal antibody ramucirumab. *Ann Oncol*. 2017;28:2932–42. <https://doi.org/10.1093/annonc/mdx514>.
- Amitay-Laish I, Stemmer SM, Lacouture ME. Adverse cutaneous reactions secondary to tyrosine kinase inhibitors including imatinib mesylate, nilotinib, and dasatinib. *Dermatol Ther*. 2011;24:386–95. <https://doi.org/10.1111/j.1529-8019.2011.01431.x>.
- Mukhopadhyay A, Do DV, Ong CT, Khoo YT, Masilamani J, Chan SY, et al. The role of stem cell factor and c-KIT in keloid pathogenesis: do tyrosine kinase inhibitors have a potential therapeutic role? *Br J Dermatol*. 2011;164:372–86. <https://doi.org/10.1111/j.1365-2133.2010.10035.x>.

Publisher's Note

Springer Nature remains neutral with regard to jurisdictional claims in published maps and institutional affiliations.

Ready to submit your research? Choose BMC and benefit from:

- fast, convenient online submission
- thorough peer review by experienced researchers in your field
- rapid publication on acceptance
- support for research data, including large and complex data types
- gold Open Access which fosters wider collaboration and increased citations
- maximum visibility for your research: over 100M website views per year

At BMC, research is always in progress.

Learn more biomedcentral.com/submissions

