

CASE REPORT

Open Access



The effectiveness of preoperative assessment using a patient-specific three-dimensional pseudoarticulation model for minimally invasive posterior resection in a patient with Bertolotti's syndrome: a case report

Kensuke Shinonara^{*}, Michiya Kaneko, Ryo Ugawa, Shinya Arataki and Kazuhiro Takeuchi

Abstract

Background: Bertolotti's syndrome is widely known to cause low back pain in young patients and must be considered as a differential diagnosis. Its treatment such as conservative therapy or surgery remains controversial. Surgical procedure is recommended for intractable low back pain. The three-dimensional (3D) lumbosacral transitional vertebrae anatomy should be completely understood for a successful surgery. Using an intraoperative 3D navigation and preoperative preliminary surgical planning with a patient-specific 3D plaster model contribute for safe surgery and good outcome.

Case presentation: A case of a 22-year-old Japanese male patient with intractable left low back pain due to lumbosacral transitional vertebrae with Bertolotti's syndrome. The symptom resisted the conservative treatment, and anesthetic injection at pseudoarticulation only provided a short-term pain relief. Posterior resection using intraoperative three-dimensional (3D) navigation has been performed through microendoscopic view. Pseudoarticulation was totally and successfully resected in a safe manner.

Conclusions: Preoperative surgical planning and rehearsal using a patient-specific 3D plaster model was greatly useful and effective for surgeons in performing accurate and safe pseudoarticulation resection.

Keywords: Bertolotti's syndrome, Intraoperative three-dimensional navigation, Minimally invasive resection, Three-dimensional sterical plaster model

Introduction

Bertolotti's syndrome is characterized by congenital lumbosacral transitional vertebrae (LSTV) most commonly occurring at L5 level and by enlarged transverse process

of L5 articulates or unilateral or bilateral unions with the sacral area [1]. This syndrome has been reported to result in low back pain in young patients [2].

It is typically treated with conservative therapy, such as medication, trigger point anesthetic injection, and rehabilitation. In cases of intractable low back pain, surgical intervention is considered [3–7]. Several procedures for LSTV resection have already been reported; however, performing accurate resection remains difficult due to

*Correspondence: joker1011ks@yahoo.co.jp
Department of Orthopaedic Surgery, Okayama Medical Center, National Hospital Organization, 1711-1 Tamasu, Kitaku, Okayama city, Okayama, Japan



the congenital bone defect. The three-dimensional (3D) LSTV anatomy should be completely understood for a successful surgery. Here, we present the postoperative outcome of minimally invasive LSTV resection using an intraoperative 3D navigation and the effectiveness of preoperative preliminary surgical planning using a patient-specific 3D plaster model of LSTV. The institutional review board approved this clinical case report (Okayama Medical Center, Number: 2018-181).

Case presentation

A 22-year-old Japanese man who worked as carpenter complained of chronic left low back pain for at least 6 months. He had no remarkable medical history and traumatic event for a long time. His physical examination showed no neurological deficits, such as muscle weakness and sensory changes. In the assessment of physical status, Oswestry Disability Index (ODI) [8] was 46%. Radiographs and computed tomography (CT) images showed the LSTV at the L5 level, identified as Castellvi classification type 2A [9] (Fig. 1). MRI revealed no degenerative disc changes at L5–S1 level and no compression at the left L5 exiting nerve root. Conservative treatment with non-steroidal anti-inflammatory drugs and rehabilitation was immediately initiated in accordance with the therapeutic strategy reported by Li et al for first three months [10]. Anesthetic injection at the LSTV pseudoarticulation was performed twice during next two months (Fig. 2) and provided temporary pain relief every time. However, long-term improvement was not achieved. Conservative treatment was performed for total five months (Fig. 3).

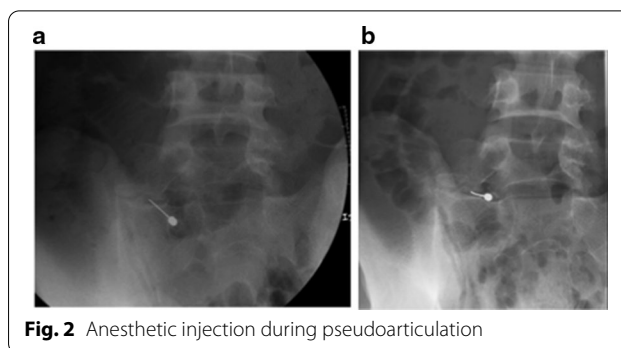


Fig. 2 Anesthetic injection during pseudoarticulation

After the recurrence of left low back pain, a minimally invasive tubular surgery was recommended.

Surgical procedure

Preoperatively, a 3D plaster model (Biotec Bones, Zimmer Biomet KK, Tokyo) of LSTV was produced using a 3D printer to sterically grasp and decide the area to be resected and was also used for training and rehearsal of the surgical procedure (Fig. 4).

The patient was placed in prone position on the operating table under general anesthesia. The navigation referential array was inserted into the right posterior iliac crest, and intraoperative images were obtained using a C-arm (Siemens, Germany) and navigation system (Brainlab, Germany). A 4.0-cm transverse incision was made over the LSTV at the left side, and the left posterior iliac crest was resected to facilitate a direct approach to the pseudoarticulation. A 1.8-mm microendoscopic tubular portal was placed strictly at the operating table, and the LSTV was resected using high-speed drill, bone

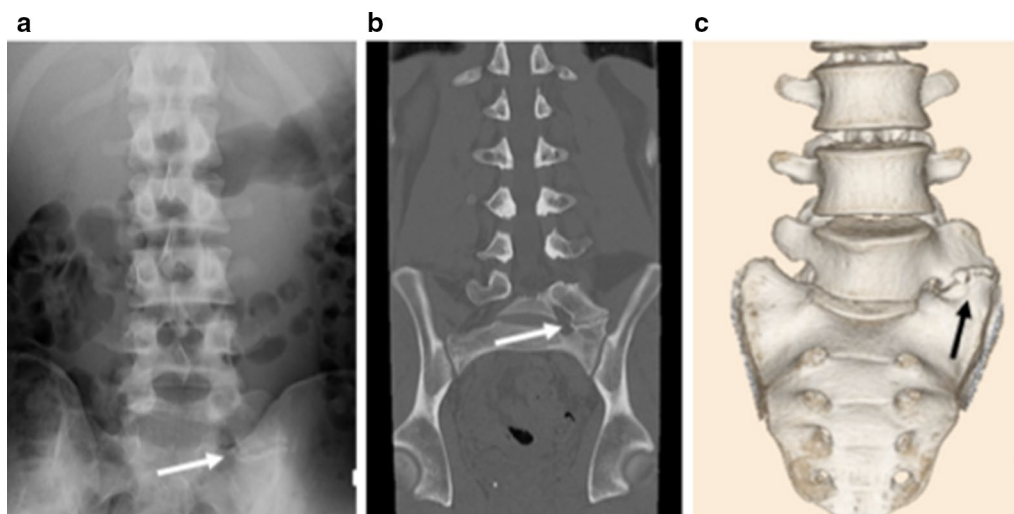


Fig. 1 **a** Preoperative anteroposterior plain radiography. **b** Preoperative coronal computed tomography (CT) image. **c** Preoperative three-dimensional (3D) CT image. Arrow indicates pseudoarticulation at the left side.

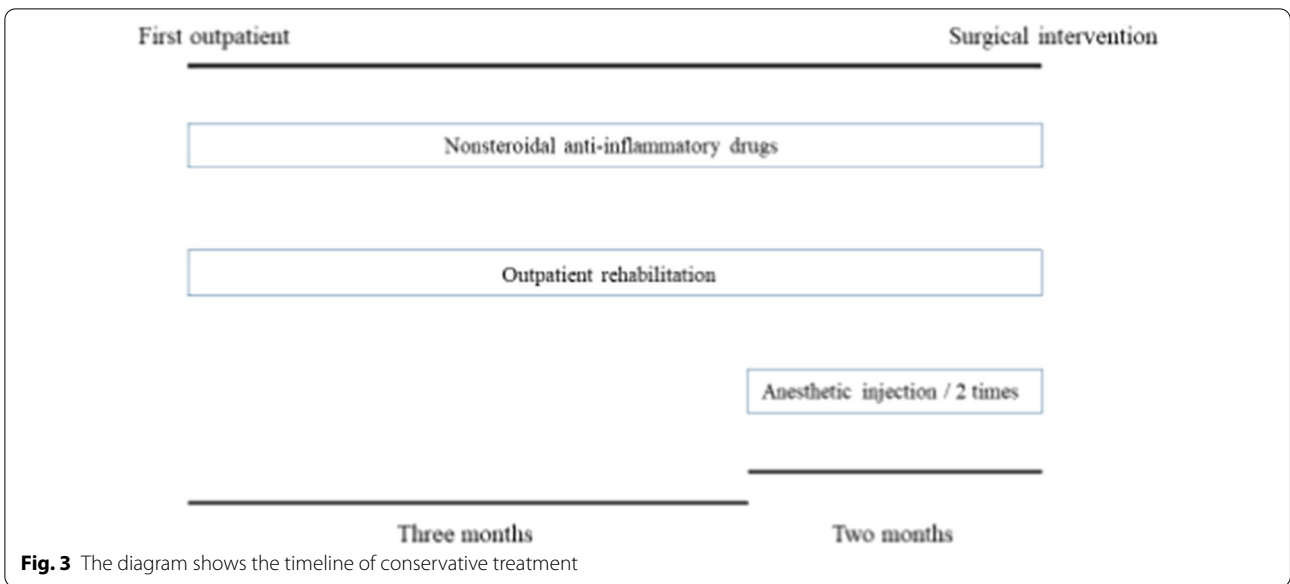


Fig. 3 The diagram shows the timeline of conservative treatment

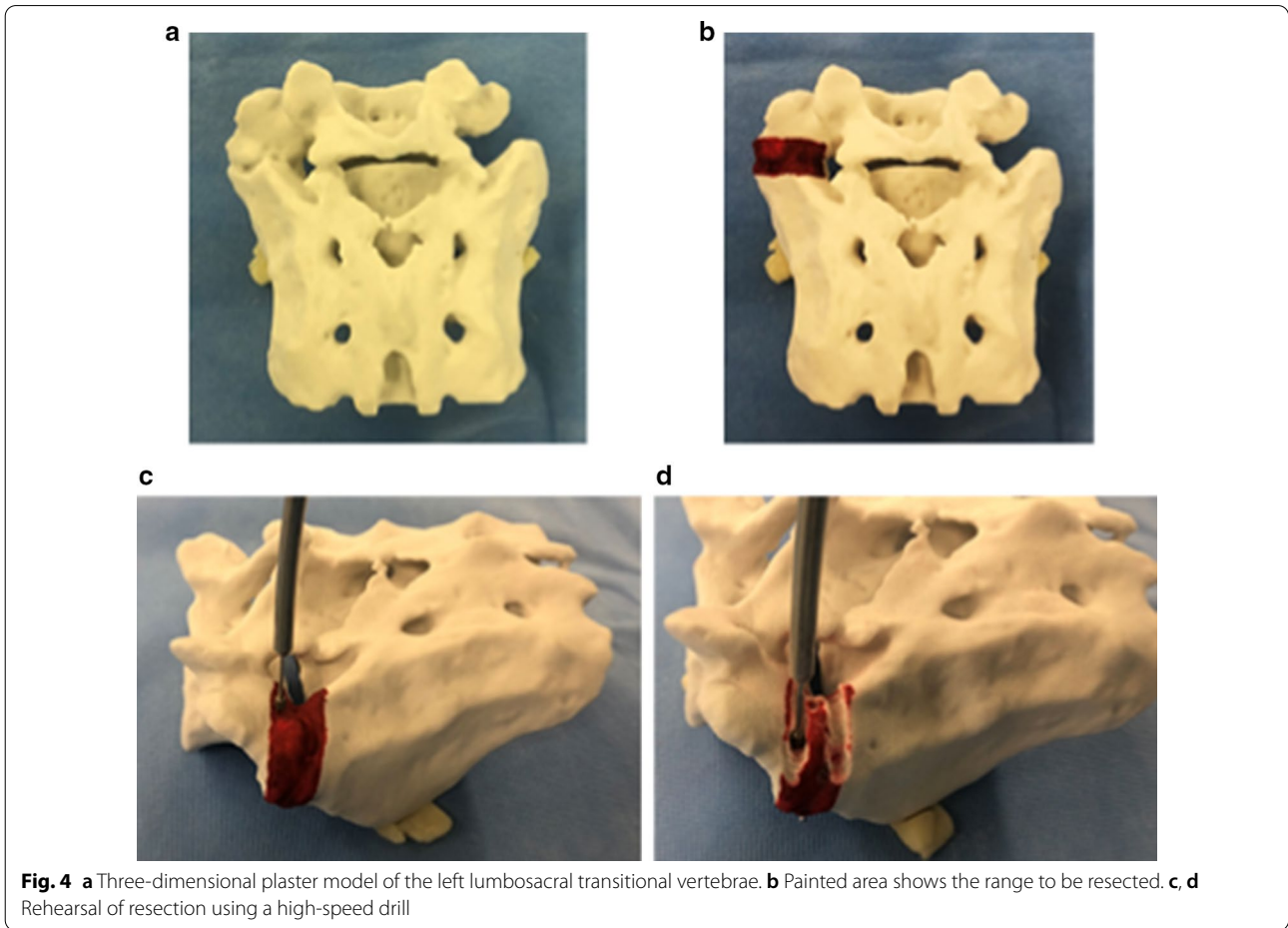


Fig. 4 **a** Three-dimensional plaster model of the left lumbosacral transitional vertebrae. **b** Painted area shows the range to be resected. **c, d** Rehearsal of resection using a high-speed drill

chisel, and Kerrison punch. The tubular portal was moved side to side during each resection. We sometimes checked the progress status of excavation using a navigation probe (Fig. 5). After the complete resection, the left iliac crest bone was returned to its original position and fixated using a fiber wire. No intraoperative and postoperative complications occurred. Postoperative radiographs and CT images showed adequate LSTV resection (Fig. 6). The patient was free from the left low back pain, and the asymptomatic status was maintained at 2 months follow up. Postoperative ODI was 6%.

Discussion

Bertolotti's syndrome was reported by Bertolotti nearly one century ago [5]. This syndrome is characterized by chronic low back pain with or without radiculopathy. Quinlan *et al.* reported that the overall incidence of Bertolotti's syndrome was 4.6% and that in young patients aged < 30 years was 11.4% [2]. However, it is commonly misdiagnosed as low back pain in young patients [11].

Castellvi *et al.* classified LSTV of Bertolotti's syndrome into four types [9], and Jancuska *et al.* reported types 2 and 4 as highly positively related with low back pain [12].

Although no consensus has been reached on its treatment, conservative therapy has been recommended as the first choice. Diagnostic algorithm and treatment strategy were described by Li *et al.* [10]. Even recently, several researchers have reported surgical options; however, the appropriate surgical method remains controversial. Although many literatures reported the use and outcome of surgical posterior resection [1, 4, 5, 10], this is the first report that used a 3D plaster model of LSTV for surgical planning and strategy identification preoperatively. The effectiveness of patient-specific 3D plaster model is to understand the details of LSTV sterically and rehearse the methods.

Intraoperative 3D navigation images helped surgeons determine the progress and depth of excavation. Additionally, navigation images will promote performance of safe surgery because the major vessels and exiting nerve roots are placed around the LSTV. Babu *et al.* reported that intraoperative 3D images and navigation guidance facilitated resection of enlarged transverse processes [13]. Therefore, the use of intraoperative 3D navigation is recommended for a safe and complete LSTV resection.

In this case, a minimally invasive posterior surgery was chosen for LSTV resection because no degenerative

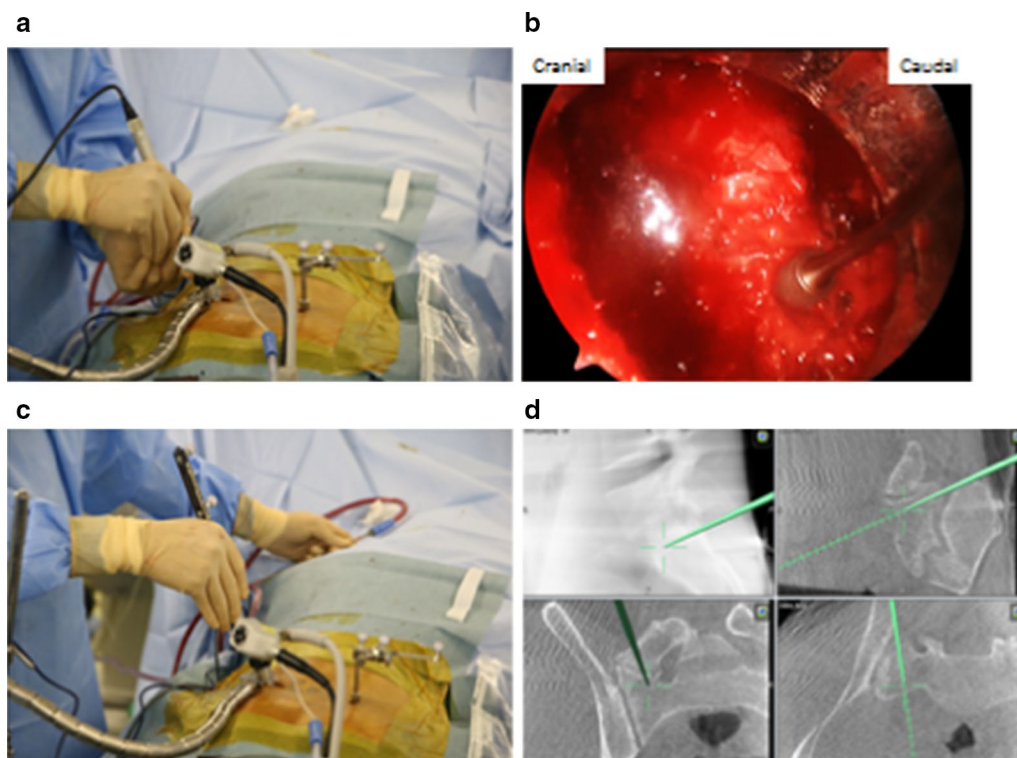


Fig. 5 **a** Placement of microendoscope at the left side and navigation of the referential array in the right iliac crest placement. Resection using a high-speed drill. **b** Intraoperative microendoscopic image. Resection of pseudoarticulation using a high-speed drill. **c** Checking the depth and progress status of excavation (real-time images are shown in **d**). **d** Intraoperative three-dimensional navigation images

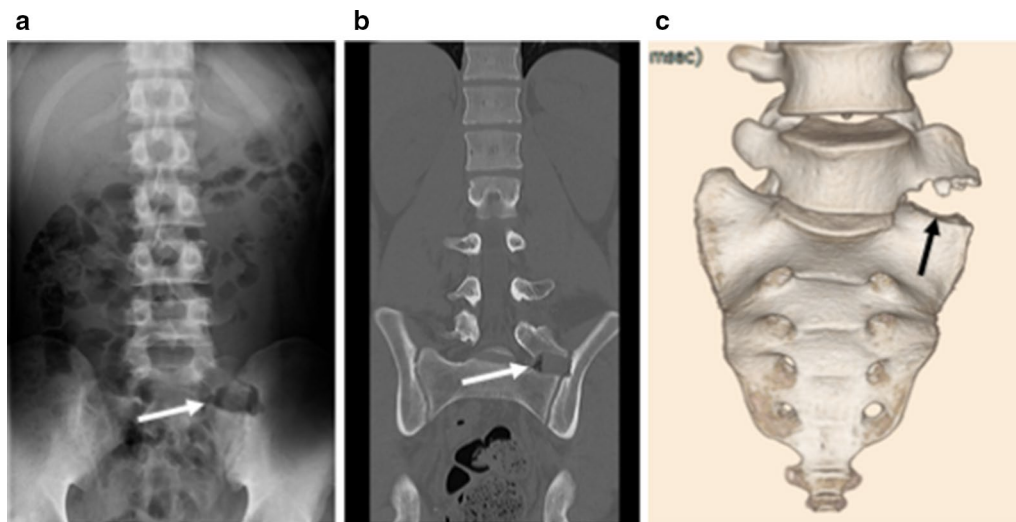


Fig. 6. **a** Postoperative anteroposterior plain radiography. **b** Postoperative coronal computed tomography (CT) image. **c** Postoperative three-dimensional (3D) CT image. Arrow indicates the removal of pseudoarthroclatation

disc changes were observed at the L5–S1 level. In young patients, minimally invasive surgery can effectively reduce postoperative changes. If the degenerative disc change is detected, fusion surgery is required.

Conclusions

Bertolotti's syndrome is effectively diagnosed not only by radiographs and CT images but also by anesthetic injections at pseudoarthroclatation. Patients with intractable low back pain associated with Bertolotti's syndrome that resisted conservative therapy can be effectively treated with minimally invasive posterior resection of LSTV. Therefore, preoperative surgical planning with a patient-specific 3D plaster model and intraoperative navigation images are suggested to be useful for surgeons, which result in a safe surgery and complete LSTV resection.

Abbreviations

LSVT: Lumbosacral transitional vertebrae; 3D: Three-dimensional; ODI: Oswestry Disability Index; CT: Computed tomography.

Acknowledgements

All of authors thank Dr. Naofumi Shiota, expert trauma surgeon in our department, for his helpful advice and comment about using navigation system and placement of navigation referential array in iliac crest.

Additionally, the authors wish to acknowledge Miss. Naomi Mitsuoka, staff of operating room at Okayama Medical Center, because she has taken a photograph of preoperative rehearsal and intraoperative pictures.

Authors' contributions

All authors were on the surgical team that performed this surgery and have been following up the patient. All authors participated equally in the writing of this manuscript. All authors read and approved the final manuscript.

Funding

The authors declare that they have no utilize fund for this report.

Availability of data and materials

Not applicable.

Ethics approval and consent to participate

This report was approved by the institutional review board (Okayama Medical Center, Number: 2018-181). The patient agreed to approve participation in this study.

Consent for publication

Written informed consent was obtained from the patient for publication of this case report and any accompanying images. A copy of the written consent is available for review by the Editor-in-Chief of this journal.

Competing interests

The authors declare they have no competing interests.

Received: 27 July 2020 Accepted: 14 December 2020

Published online: 16 February 2021

References

- Louie CE, Hong J, Bauer DF. Surgical management of Bertolotti's syndrome in two adolescents and literature review. *Surg Neurol Int.* 2019;10:135.
- Quinlan JF, Duke D, Eustace S. Bertolotti's syndrome. A cause of back pain in young people. *J bone Joint Surg Br.* 2006;88:1183–6.
- Malham GM, Limb RJ, Claydon MH, et al. Anterior pseudoarthrectomy for symptomatic Bertolotti's syndrome. *J Clin Neurosci.* 2013;20:1762–6.
- Takata Y, Sasaki T, Higashino K, et al. Minimally invasive microendoscopic resection of the transverse process for treatment of low back pain with Bertolotti's syndrome. *Case Rep Orthop.* 2014; 613971
- Yousif S, Wood M. Minimally invasive resection of lumbosacral pseudo-joint resulting in complete resolution of a lower back pain—a case report and review of Bertolotti's syndrome. *J Clin Neurosci.* 2018;51:67–8.
- Adams R, Nicol SH, Jenkins A. Surgical treatment of a rare presentation of Bertolotti's syndrome from Castellvi type IV lumbosacral transitional vertebra: case report and review of literature. *J Neurol Surg Rep.* 2018;79:e70–4.
- Santavirta S, Tallroth K, Ylien P, et al. Surgical treatment of Bertolotti's syndrome. Follow-up of 16 patients. *Arch Orthop Trauma Surg.* 1993;112:82–7.

8. Fujiwara A, Kobayashi N, Saiki K, et al. Association of the Japanese Orthopaedic Association score with the Oswestry Disability Index, Roland-Morris Disability Questionnaire, and short-form 36. *Spine*. 2003;28:1601–7.
9. Castellvi AE, Goldstein LA, Chan DP. Lumbosacral transitional vertebrae and their relationship with lumbar extradural defects. *Spine*. 1984;9:493–5.
10. Li Y, Lubelski D, Abdullah KG, et al. Minimally invasive tubular resection of the anomalous transverse process in patients with Bertolotti's syndrome. *J Neurosurg Spine*. 2014;20:283–90.
11. Manmohan S, Dzulkarnain A, Nor Azlin ZA, et al. Bertolotti's syndrome: a commonly missed cause of back pain in young patients. *Malays Fam Physician*. 2015;10:55–8.
12. Jancuska JM, Spivak JM, Bendo JM, et al. A review of symptomatic lumbosacral transitional vertebrae: Bertolotti's syndrome. *Int J Spine Surg*. 2015;9:42.
13. Babu H, Lagman C, Kim TT, et al. Intraoperative navigation-guided resection of anomalous transverse processes in patient with Bertolotti's syndrome. *Surg Neurol Int*. 2017;8:236.

Publisher's Note

Springer Nature remains neutral with regard to jurisdictional claims in published maps and institutional affiliations.

Ready to submit your research? Choose BMC and benefit from:

- fast, convenient online submission
- thorough peer review by experienced researchers in your field
- rapid publication on acceptance
- support for research data, including large and complex data types
- gold Open Access which fosters wider collaboration and increased citations
- maximum visibility for your research: over 100M website views per year

At BMC, research is always in progress.

Learn more biomedcentral.com/submissions

