

CASE REPORT

Open Access



Bladder rupture due to urogenital tract trauma caused by ox horn injury in a patient with pelvic organ prolapse: a case report

Zelalem Mengistu* and Mezigebeu Molla

Abstract

Introduction: Genitourinary tract trauma caused by ox horn injury in the presence of pelvic organ prolapse (POP) is an extremely rare phenomenon and associated with devastating morbidity.

Case presentation: A 50-year-old multiparous postmenopausal woman from rural northwest Ethiopia presented with the primary complaint of urinary incontinence 6 days after she suffered ox horn injury to her prolapsed genitalia. She had stage 3 pelvic organ prolapse with the leading point being the cervix. The anterior vaginal and posterior bladder walls were disrupted with visible draining of the left ureter. The wound was dirty and edematous with whitish discharge. She was admitted to the urogynecology ward and provided with wound care until the infection subsided. Apical prolapse suspension was performed using right sacrospinous fixation, and bladder repair was carried out 6 weeks following the prolapse suspension. She recovered well and was continent when discharged.

Conclusion: Ox horn injury involving the female lower urogenital tract in the presence of POP is extremely rare. Late presentation after sustaining injury is associated with increased risk of morbidity and long hospital stay, and treatment requires multistage surgery.

Keywords: Horn injury, Urogenital injury, Genital trauma, Bladder rupture, Pelvic organ prolapse injury

Introduction

Traumatic injury to the female genital tract includes external injuries to the labia, vulva or vagina, urethra and anus and internal injuries to the bony pelvis, bladder, bowels and reproductive organs [1]. Obstetric complications are the most common cause of female urogenital trauma, although non-obstetric causes are not unusual. However, non-obstetric injury to the lower genitourinary tract in females has not been well described in the literature. The non-obstetric causes of genital trauma are classified as coital or non-coital. The majority of non-coital causes result from striking injuries (edge of chairs, stools, sharp object etc.), road traffic accidents, violence,

bull horn injury and genital mutilation [2, 3]. The risk factors associated with non-birth-related injury to the genital tract are age, marital status, residential location, occupation, socioeconomic status, leisure and sporting activities and sexual behavior [4].

Although physical traumas resulting from cattle horn injuries are relatively common on various parts of the body, injuries to the genitalia and lower urinary system from cattle horns are rarely reported [5, 6].

Urogenital tract trauma accounts for 10% of all abdominopelvic traumatic injuries of which bladder injury occurs in 1.6% of these cases [7, 8]. Injury to the bladder is not common due to the protection provided by the bony pelvis. Bladder injury is usually associated with a high-impact trauma [8, 9]. Among bladder injuries, bladder rupture is a rare phenomenon. Bladder rupture can be either extraperitoneal (EP) or intraperitoneal (IP).

*Correspondence: emushe10@yahoo.com

Department of Obstetrics and Gynecology, University of Gondar, Gondar, Ethiopia



© The Author(s) 2020. **Open Access** This article is licensed under a Creative Commons Attribution 4.0 International License, which permits use, sharing, adaptation, distribution and reproduction in any medium or format, as long as you give appropriate credit to the original author(s) and the source, provide a link to the Creative Commons licence, and indicate if changes were made. The images or other third party material in this article are included in the article's Creative Commons licence, unless indicated otherwise in a credit line to the material. If material is not included in the article's Creative Commons licence and your intended use is not permitted by statutory regulation or exceeds the permitted use, you will need to obtain permission directly from the copyright holder. To view a copy of this licence, visit <http://creativecommons.org/licenses/by/4.0/>. The Creative Commons Public Domain Dedication waiver (<http://creativecommons.org/publicdomain/zero/1.0/>) applies to the data made available in this article, unless otherwise stated in a credit line to the data.

EP ruptures are more common and usually result from forceful impact to the anterior bladder [8, 9], while IP ruptures usually result from a rise in intravascular pressure following an abdominopelvic impact that causes rupture of one of the weaker points of the bladder, such as the dome [10].

We present a case of bladder rupture in a postmenopausal woman with stage three pelvic organ prolapse (POP) that resulted from an injury caused by an ox horn. The patient was successfully treated and was continent at discharge.

Written informed consent was obtained from the patient for publication of this case report and accompanying images.

Case presentation

A 50-year-old postmenopausal woman, gravida 15, para 7, from a rural area in northwest Ethiopia presented to the University of Gondar Urogynecology unit after she sustained an ox horn injury to her genitalia 6 days prior to presentation. She initially had profuse bleeding from the injury site, but the bleeding stopped spontaneously and she did not seek medical care until she presented to our urogynecology unit. At presentation, she reported a history of failure to control urine and pain, and a foul-smelling discharge at the wound site. She had history of a mass protruding outside the vagina of 7 years duration that was progressively increasing and associated with difficulty in urinating for which she had not sought medical care. Following the injury she denied abdominal pain, abdominal distension or failure to pass feces and flatus. Her last menses was 2 years prior to the injury. She had no known history of other medical problems or illness.

On physical examination she was acutely sick looking, vital signs were within normal range and she had slightly pale conjunctiva. Her abdomen was flat, non-tender and

with active bowel sounds with no palpable mass or sign of fluid collection. Evaluation of the genitourinary system revealed stage three POP with the leading point being the cervix. The anterior vaginal and posterior bladder walls were disrupted with visible draining of the left ureter. The wound was dirty and edematous with a whitish discharge (Fig. 1). There was no involvement of the urethra and the distal one-third of the vagina in the injury. She had difficulty walking due to the pain from the wound. Otherwise there were no remarkable findings from her physical examination. Her hematocrit was 31.6%, and abdominopelvic ultrasound revealed a mild right-sided hydronephrosis with hydroureter. There was no sign of intra-abdominal or pelvic fluid collection. She was admitted to the urogynecology ward with a diagnosis of stage three POP, posterior bladder rupture and wound infection. The right ureteral orifice was identified and stented (Fig. 2), and she received wound care twice daily.

Three months following admission, the wound was clean and well granulated and the edema had resolved. The right sacrospinous ligament fixation was then completed (Figs. 3 and 4).

Six weeks after the RSSF the ruptured bladder was repaired after adequate mobilization of the bladder

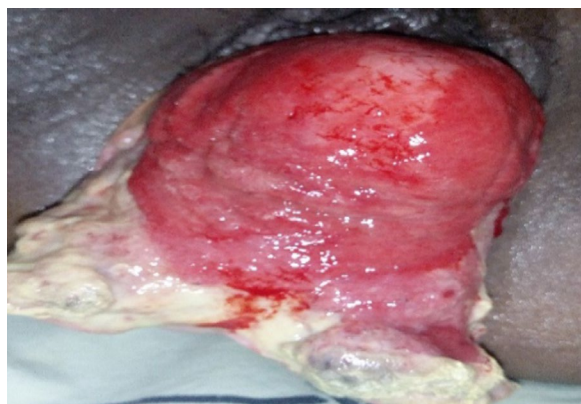

Fig. 1 Edematous and infected ruptured bladder at admission

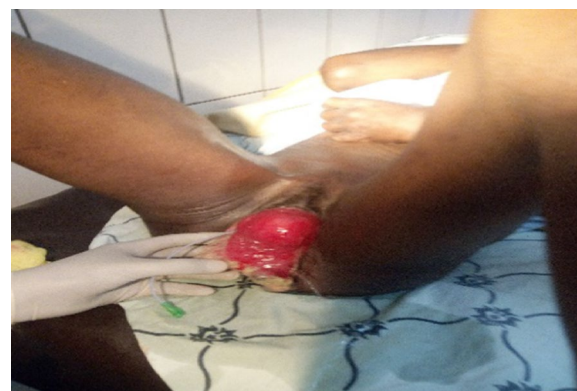

Fig. 2 Stented right ureter

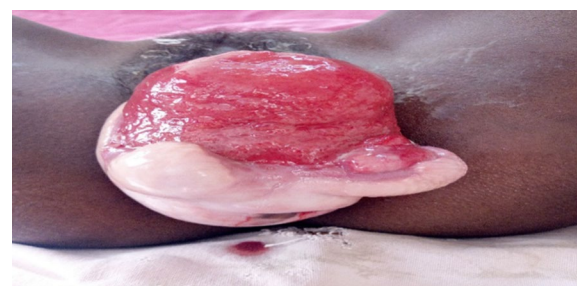


Fig. 3 Stage III pelvic organ prolapse with ruptured bladder before right sacrospinous ligament fixation

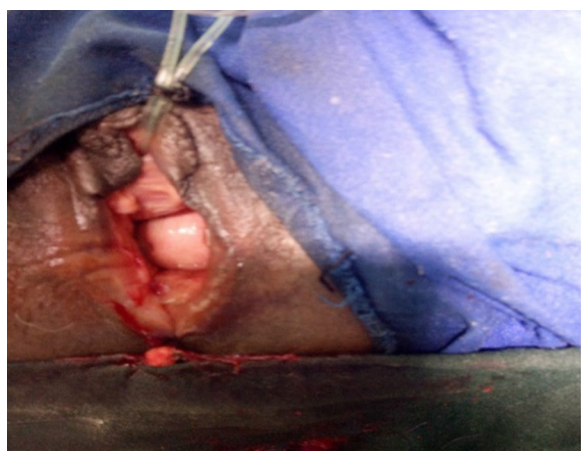

Fig. 4 After apical repair with right sacrospinous ligament fixation

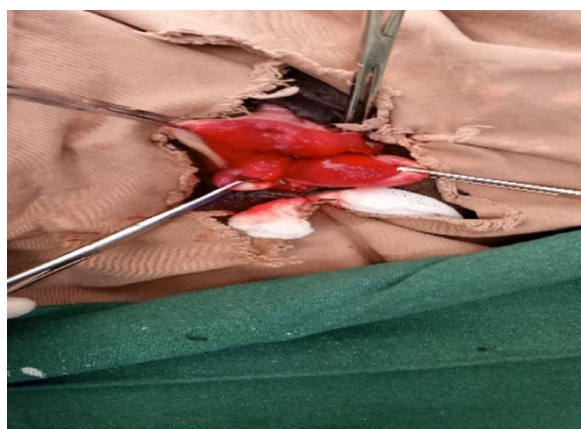


Fig. 5 Ruptured bladder before repair

(Fig. 5). Both the ureters were identified and stented prior to the repair. Vaginal packing and transurethral catheter were left in situ. The vaginal packing and the urinary catheter were removed after 24 hours and 3 weeks, respectively. The patient was fully continent when discharged on postoperative day 21 following bladder repair and on postoperative day 63 following her RSSF.

Discussion

Physical trauma to the urogenital system due to horn injury is a rare phenomenon as the level of this system is lower than the head of the bull and the perineum is a highly protected region due to the reflex adduction of the thigh [5, 11]. However, depending on the relative positions of the bull's head and the victim an injury may occur to any part of the body [12]. This is clearly illustrated in our case, in which the patient was in squatting

position preparing food for her cattle. A 5-year retrospective review of hospital data on lower genitourinary tract trauma in females caused by cow horn injury identified only 12 cases of such injuries, and none involved the bladder [6].

The relevance of this case is its uniqueness as no similar case has been reported to date. Lacerations to the female lower genitourinary system caused by bull horn injuries are usually limited to the lower vagina because the horns are long, curved and directed forwards with tapering edges. Bull horns can also penetrate body cavities, such as the bladder [4, 5, 13]. Among possible bladder injuries, bladder rupture resulting from horn injury, as seen in our patient, is an extremely rare phenomenon. In the case of our patient, however, the rupture of the bladder was due to the penetrative horn injury disrupting the anterior vaginal wall and the base of the bladder. One possible contributory factor to this atypical injury may have been the presence of advanced stage POP in this woman. The slow healing of the wound was due to the late presentation and the postmenopausal state. She stayed at the hospital for > 3 months due to two-staged surgery because postmenopausal hypo-estrogenic changes had induced thinning and atrophy of the vulvo-vaginal epithelium as well as vaginal lubrication [4].

Conclusion

Ox horn injury involving the female genitourinary tract and resulting bladder rupture is extremely rare. The presence of advanced-stage POP increases the risk of severe complications. Late presentation will result in delayed repair and a longer hospital stay.

Abbreviations

EP: Extraperitoneal; IP: Intraperitoneal; POP: Pelvic organ prolapse; RSSF: Right sacrospinous ligament fixation.

Acknowledgements

We would like to acknowledge the kind comments and guidance of Dr. Kristen Austin on this case report

Authors' contributions

ZM and MM were responsible for the concept, ZM and MM wrote the paper, and the manuscript was reviewed and edited by ZM and MM. Both authors read and approved the final version of the manuscript and take responsibility for the integrity of the work as a whole.

Ethics approval and consent to participate

We would like to declare the need for approval is waived for the case report by our institutional review board (IRB).

Consent for publication

Written informed consent was obtained from the patient for publication of this case report and accompanying images. A copy of the written consent is available for review by the Editor-in-Chief of this journal.

Competing interests

The authors declare that they have no competing interests.

Received: 11 September 2020 Accepted: 8 October 2020

Published online: 24 November 2020

References

- Lopez HN, Focseneanu MA, Merritt DF. Genital injuries acute evaluation and management. *Best Pract Res Clin Obstet Gynaecol*. 2018;48:28–39. <https://doi.org/10.1016/j.bpobgyn.2017.09.009>.
- Sau AK, Dhar KK, Dhall GI. Nonobstetric lower genital tract trauma. *Aust N Z J Obstet Gynaecol*. 1993;33(4):433–35.
- PR Sill. Non-obstetric female genital tract trauma in Port Moresby, Papua New Guinea. *Aust N Z J Obstet Gynaecol*. 1987;27(2):164–165.
- Gupta A, Sharma C, Soni A, Gupta B, Thusoo M. Unusual lower genital tract injury caused by bull's horn: prolapse of small intestine through vagina—first case report in literature. *Arch Gynecol Obstet*. 2012;286(3):803–804.
- Kulkarni MR, Gangadharaiah M, Kulkarni SR. Bull gore injury of the vagina. *J Clin Diagn Res*. 2013;7(1):158–159.
- Priyadarshi V, Gupta D, Pal DK. Lower genitourinary tract trauma caused by cow horn injury. *J Obstet Gynecol India*. 2016;66(1):578–582.
- Bryk DJ, Zhao LC. Guideline of guidelines: a review of urological trauma guidelines. *BJU Int*. 2016;117(2):226–234.
- Gomez RG, Ceballos L, Coburn M, Corriere JN, Dixon CM, Lobel B. Consensus statement on bladder injuries. *BJU Int*. 2004;94(1):27–32.
- Guttmann I, Kerr HA. Blunt bladder injury. *Clin Sports Med*. 2013;32(2):239–246.
- Barnard J, Overholt T, Hajiran A, Crigger C, Jessop M, Knight J. Traumatic bladder ruptures: a ten-year review at a level 1 trauma center. *Adv Urol*. 2019;2019:2614586.
- Shukla HS, Mittal DK, Naithani YP. Bull horn injury: a clinical study. *Injury*. 1977;9(2):164–167.
- Santhosh R, Kumar Barad A, Sureshwara Ghalige H, Sridartha K, Birkumar SM. Perineal bull gore with urinary bladder perforation and pneumoperitoneum. *J Clin Diagn Res*. 2013;7(5):902–904.
- Kulkarni SR, Biradar SB, Nagur BK, Reddy M, Savsaviya JK. Bull horn injuries in rural area: a case series. *Int J Sci Study*. 2016;3(10):201–203.

Publisher's Note

Springer Nature remains neutral with regard to jurisdictional claims in published maps and institutional affiliations.

Ready to submit your research? Choose BMC and benefit from:

- fast, convenient online submission
- thorough peer review by experienced researchers in your field
- rapid publication on acceptance
- support for research data, including large and complex data types
- gold Open Access which fosters wider collaboration and increased citations
- maximum visibility for your research: over 100M website views per year

At BMC, research is always in progress.

Learn more biomedcentral.com/submissions

