

CASE REPORT

Open Access



Renal cell carcinoma metastasis to the maxillary bone successfully treated with surgery after vascular embolization: a case report

Naoto Nishii^{1*} , Hiroaki Shimamoto¹, Toshimitsu Ohsako¹, Misaki Yokokawa¹, Yuriko Sato¹, Yae Ohata², Kou Kayamori², Tohru Ikeda² and Hiroyuki Harada¹

Abstract

Background: Metastasis of renal cell carcinoma to the oral cavity is rare. Renal cell carcinoma metastases are regarded as radioresistant tumors and surgery is recommended. However, since metastatic renal cell carcinoma has poor prognosis and is composed of abundant blood vessels, it is sometimes difficult for clinicians to choose surgical therapy. Here, we report a case of a patient with renal cell carcinoma metastasis to the maxillary bone, which was successfully controlled by surgical therapy after vascular embolization, and provide a detailed literature review regarding the treatments and outcomes of renal cell carcinoma metastasis to the oral cavity.

Case presentation: An 89-year-old Japanese man presented with an 8 × 8-mm granulomatous tumor with palpable pulsation in the left upper gingiva, which had been clinically suspected as an arteriovenous malformation or neoplastic lesion with rich blood vessels. Our patient had undergone left nephrectomy for clear cell carcinoma 7 years prior. Pulmonary metastasis had appeared 3 years later. After intravascular embolization, our patient underwent tumor resection of the maxilla with little intraoperative blood loss. The tumor was diagnosed on histopathology as a metastasis of clear cell renal cell carcinoma to the maxillary bone. Seventeen months after surgery, he died because of pulmonary metastasis without evidence of recurrence in the oral cavity.

Conclusions: Our literature review reveals that oral metastatic lesions of renal cancer often exhibit rapid enlargement and cause severe symptoms, such as dysphagia and bleeding. Although oral metastasis of renal cell carcinoma has a poor prognosis due to the presence of concurrent disseminated metastases, surgical therapy may be recommended because of its high local control rate and ability to maintain quality of life. Preoperative vascular embolization is considered to be effective to reduce intraoperative hemorrhage, which leads to safe surgery.

Keywords: Renal cell carcinoma, Metastasis, Oral cavity, Maxillary bone, Pulsatile lesion, Preoperative vascular embolization

* Correspondence: nishii.osur@tmd.ac.jp

¹Department of Oral and Maxillofacial Surgery, Graduate School of Medical and Dental Sciences, Tokyo Medical and Dental University, 1-5-45 Yushima, Bunkyo-ku, Tokyo 113-8549, Japan

Full list of author information is available at the end of the article



© The Author(s). 2020 **Open Access** This article is licensed under a Creative Commons Attribution 4.0 International License, which permits use, sharing, adaptation, distribution and reproduction in any medium or format, as long as you give appropriate credit to the original author(s) and the source, provide a link to the Creative Commons licence, and indicate if changes were made. The images or other third party material in this article are included in the article's Creative Commons licence, unless indicated otherwise in a credit line to the material. If material is not included in the article's Creative Commons licence and your intended use is not permitted by statutory regulation or exceeds the permitted use, you will need to obtain permission directly from the copyright holder. To view a copy of this licence, visit <http://creativecommons.org/licenses/by/4.0/>. The Creative Commons Public Domain Dedication waiver (<http://creativecommons.org/publicdomain/zero/1.0/>) applies to the data made available in this article, unless otherwise stated in a credit line to the data.

Background

Tumor metastasis to the oral cavity is uncommon, comprising only 1% of all oral malignant tumors [1]. After lung and breast carcinoma, renal carcinoma is the third most common tumor that metastasizes to the head and neck [2]. Because oral metastasis of renal cell carcinoma (RCC) is a late-stage phenomenon, often accompanied by lung metastasis, its prognosis is very poor [3]. RCC metastases are often regarded as radioresistant tumors, and surgical treatment is recommended. However, given the poor prognosis of metastatic RCC to the oral cavity, careful consideration is necessary regarding whether surgery can improve quality of life for end-stage oncological patients. In this report, we describe a patient with RCC metastasis that developed in the maxillary bone, which was successfully controlled by surgical treatment after vascular embolization. We provide a review of the current literature and discuss the treatment regarding oral cavity involvement of RCC metastasis.

Case presentation

An 89-year-old Japanese man noticed swelling of the left maxillary gingiva in November 2016. In December 2016, he was referred to our department because the mass had slowly enlarged. His past medical history included clear cell RCC in his left kidney 7 years prior, which had been treated by nephrectomy. Multiple pulmonary metastases of RCC had appeared 3 years after surgery. He had received molecular targeted therapy with sorafenib for 4 years, which suppressed the growth of pulmonary metastases. Intra-oral examination showed an 8 × 8 mm granulomatous tumor with palpable pulsation in the buccal side of the left upper gingiva (Fig. 1a). The lesion enlarged rapidly over 2 weeks (Fig. 1b), and our patient began to feel pain while eating.

Panoramic radiography revealed resorption of the left maxillary alveolar bone (Fig. 2a). Enhanced computed tomography showed a tumor destroying the left maxillary bone as well as the anterior and lateral

walls of the maxillary sinus (Fig. 2b). Magnetic resonance imaging showed a 47 × 31 × 22 mm mass in the left maxillary bone and maxillary sinus, which extended into the oral cavity (Fig. 2c). Computed tomography angiography demonstrated that the mass in the left maxillary bone had strong enhancement and was fed by the infraorbital artery, posterior superior alveolar artery, and sphenopalatine artery (Fig. 2d). Our patient was clinically suspected to have an arteriovenous malformation or neoplastic lesion in the left maxilla.

In January 2017, 5 days after intravascular embolization of three feeding arteries, our patient underwent maxillary tumor resection. Pulsation around the tumor was not palpable after embolization. Prior to surgery, a biopsy specimen of the left maxillary gingiva had been subjected to frozen study. The results indicated that metastasis of the previously treated RCC could not be ruled out. Subtotal maxillectomy was performed by an intraoral approach (Fig. 3). Intraoperative blood loss was only 26 ml. After surgery, there was no problems with oral intake of the patient. Although no tumor recurrence was observed in the oral cavity, our patient died 17 months after surgery because of widespread pulmonary metastases.

Histologically, the neoplastic cells were arranged in an alveolar pattern with intervening delicate vascular stroma (Fig. 4a). The tumor cells displayed round to polygonal nuclei, with mild to moderate atypia, and large amounts of clear cytoplasm (Fig. 4b). Periodic acid–Schiff-positive granules were found in some tumor cells (Fig. 4c). Immunohistochemistry staining revealed that the tumor cells were positive for CD10 and AE1/3 (Fig. 4d, e). The tumor was diagnosed on histopathology as a metastasis of clear cell RCC to the maxillary bone.

Discussion

Nearly one in three patients with RCC develops distant metastatic disease. The most common site of distant metastasis is lung (75%), followed by bone

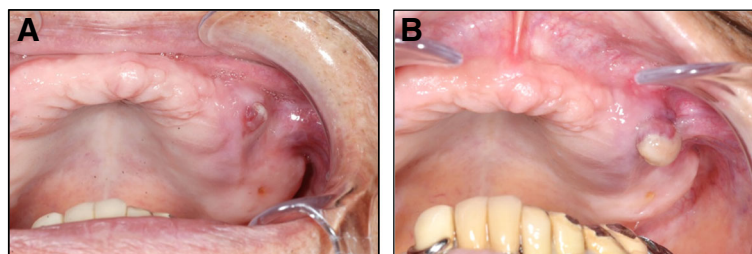


Fig. 1 a Intraoral photograph of tumor of the left upper gingiva at the first visit, showing granulomatous appearance. **b** Tumor enlarged rapidly in 2 weeks

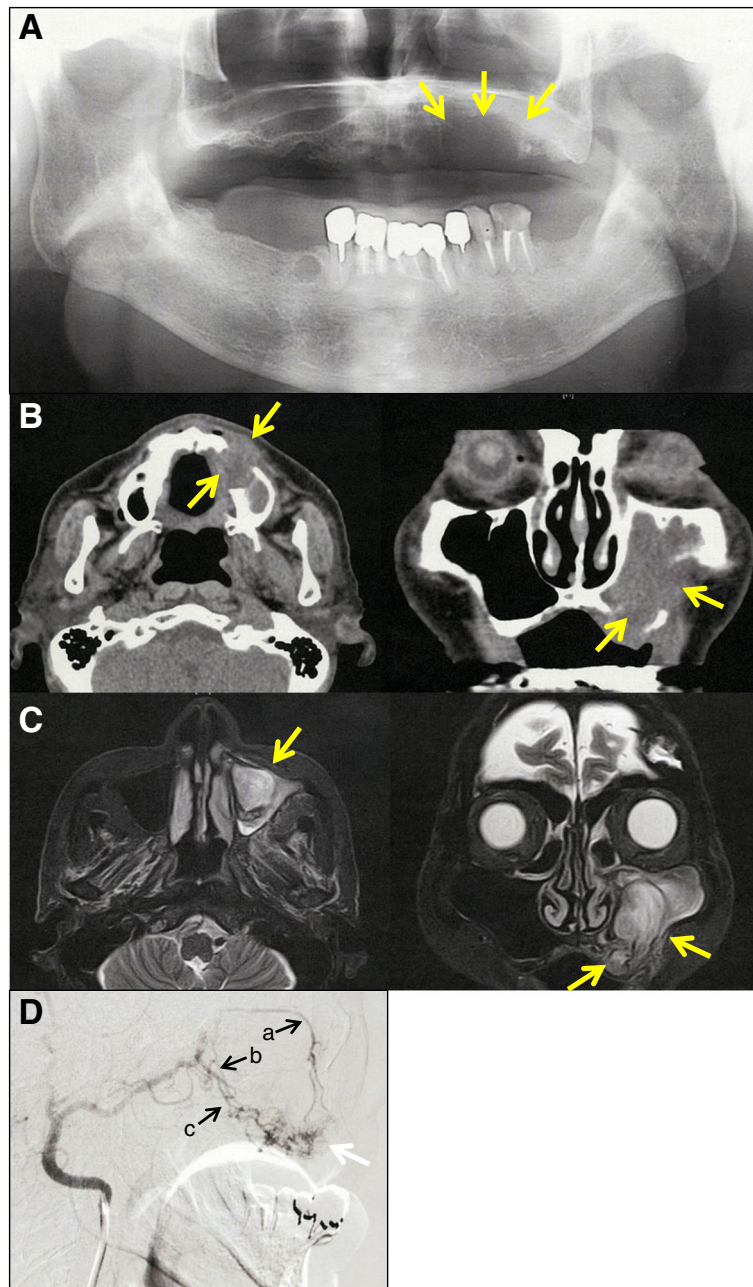


Fig. 2 **a** Panoramic radiography revealed resorption of left maxillary alveolar bone (arrow). **b** Enhanced computed tomography showed a tumor destroying the left maxillary bone (arrow). **c** Magnetic resonance imaging showed a 47 × 31 × 22 mm mass in the left maxillary bone and maxillary sinus (arrow). **d** Computed tomography angiography showed a mass with strong enhancement (white arrow) fed by the infraorbital artery (**a**), sphenopalatine artery (**b**), and posterior superior alveolar artery (**c**)

(20%), and liver (18%) [4]. Metastasis of RCC to the head and neck region is relatively rare, with a reported incidence of 15% [5]. A literature review revealed 153 patients with renal carcinoma metastasizing to the oral cavity from 1970 to 2020 [3, 5–40] (Table 1). Male patients were more frequently affected than female patients (male to female ratio, 3:1), with ages ranging between

1 and 89 years (mean age, 61.4 years). The tongue was involved in renal metastases in most patients (62 patients, 39.5%). Ninety-three patients were diagnosed with oral metastatic lesions after primary renal cancer. The duration from the onset of renal cancer to oral metastasis ranged from 2 weeks to 26 years, with an average of 4.8 years.

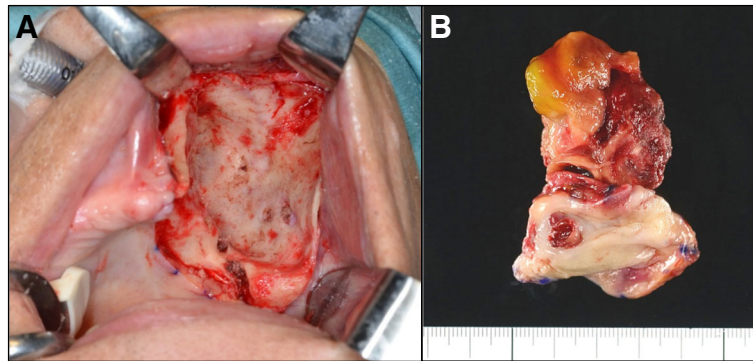


Fig. 3 **a** Intraoperative photograph after tumor and surrounding bone were removed. **b** Surgical specimen

More than three-quarters of patients with oral metastasis from renal carcinoma also exhibited other metastatic lesions, primarily lung metastases (86 patients, 59.3%) (Table 1). Because of the high rate of lung metastases, the prognosis is reported to be very poor; most patients die within the first year after diagnosis [3]. Regarding treatments, surgery is often recommended due to the ability of metastatic RCC to be resistant to radiotherapy and pharmacotherapy, including chemotherapy, molecularly targeted therapy, or immunotherapy [41]. However, considering the poor prognosis of oral metastasis of renal cancer, clinicians have to weigh the benefits of surgery and the disadvantages of not having it.

Oral metastatic lesions of renal cancer are known to undergo extremely rapid enlargement, which results in severe symptoms and a decline in quality of life. Dysphagia was observed in 18 patients (Table 1). Obstruction of the upper airways due to rapid

growth of oral metastasis led to tracheotomy in one patient [18] and death in one patient [16]. Mazon *et al.* described a patient with RCC metastasis to the tongue, who initially decided against surgery due to the poor prognosis. However, doctors were later forced to perform surgery because of a rapid increase in the size of the intraoral mass and resistance of the tumor to chemoradiotherapy [23]. In the present case, our patient began to feel pain because of the rapid increase of the intraoral mass. It was possible that dysphagia or obstruction of upper airway may have occurred without surgery, suggesting that surgical therapy can maintain quality of life of the patient.

Among 153 patients with oral metastasis of RCC described in the literature, the treatment and outcome of the oral lesion were described for 78 patients, which are summarized in Table 2. Surgery was performed in most patients (53 cases), and the

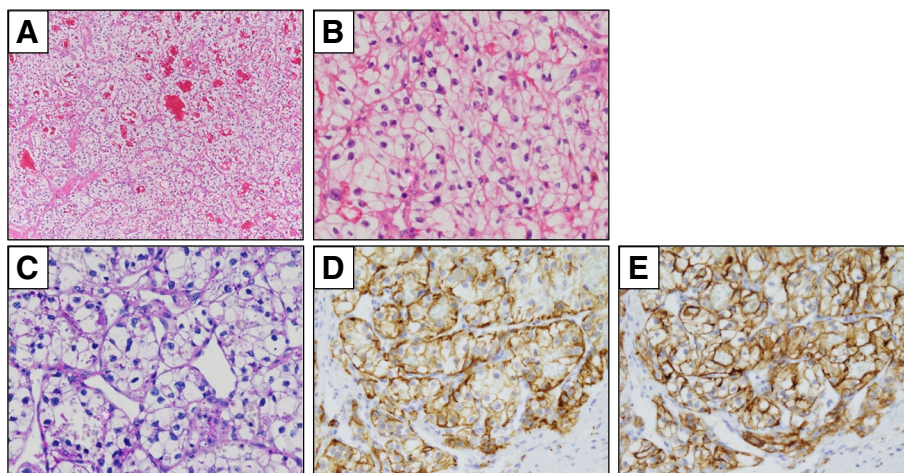


Fig. 4 Histological findings of renal cell cancer metastasis to maxillary bone. Hematoxylin and eosin staining identified clear cell differentiation with delicate vascular stroma (**a**, $\times 100$) and cellular atypia (**b**, $\times 400$). Periodic acid–Schiff staining revealed positive granules in tumor cells (**c**, $\times 400$). Immunohistochemical staining revealed positivity for AE1/3 (**d**, $\times 400$) and CD10 (**e**, $\times 400$)

Table 1 Characteristics of patients (N = 153)

Gender	
Men	113
Women	38
Not described	2
Age (yr), range (mean)	1–89 (61.4)
Oral metastatic site (%)	
Tongue	62 (39.5)
Mandibular bone	30 (19.1)
Gingiva	29 (18.5)
Palate	11 (7.0)
Maxillary bone	7 (4.5)
Buccal mucosa	6 (3.8)
Lip	5 (3.2)
Floor of mouth	3 (1.9)
Metastatic site other than oral cavity (%)	
Lung	86 (59.3)
Bone	36 (24.8)
Brain	15 (10.3)
Lymph node	15 (10.3)
Liver	11 (7.6)
Adrenal gland	9 (6.2)
Skin	5 (3.4)
Mediastinum	4 (2.8)
Muscle	4 (2.8)
None	34 (23.4)
Timing of diagnosis of oral metastasis	
Before the diagnosis of primary renal carcinoma	58
After the diagnosis of primary renal carcinoma	93
Not described	2
Time ^a , range (mean)	2 w – 26 yr (4.8 yr)
Symptom	
Bleeding	27
Dysphagia	18
Pulsation	7

w week, yr year

^aThe time from the onset of primary renal carcinoma to the metastasis of oral cavity

local control rate was greater than 90%. In contrast, the local control rates of radiotherapy, pharmacotherapy, and palliative surgery (debulking and cryosurgery) ranged from 33.3% to 66.7%. Considering the high ratio of local control after surgery, surgical therapy before further disease progression may be the first choice for patients with oral metastasis of RCC.

However, hemorrhage was observed in many patients because RCC is characterized by rich blood vessels, which makes surgery difficult. Pulsation was observed in seven patients at the first visit [7, 9–11, 16]. Three of

Table 2 Therapeutic outcomes of oral metastatic lesion of renal cell cancer. (N = 78)

Treatment	Outcome		
	Controlled ^a	Uncontrolled	Control ratio (%)
S	41	2	95.2
S + P/R	12	1	92.3
PS	3	3	50.0
R	4	3	57.1
P	2	4	33.3
P + R	2	1	66.7

P pharmacotherapy, P/R pharmacotherapy and/or radiotherapy, PS palliative surgery, R radiotherapy, S surgery

^a“Controlled” indicates no local recurrence after surgery, or regression of tumor after PS/P/R

these patients exhibited pulsation in the maxillary bone [11] (Tables 1 and 3). In our patient, arteriovenous malformation was clinically suspected due to pulsation. Past reports indicated that two patients with mandibular lesions were also clinically diagnosed with vascular malformation, then diagnosed with RCC metastases upon pathological examination [8, 10]. Twenty-seven patients exhibited bleeding at the first visit or during follow-up, which resulted in death in one case [31]. Ten patients had difficulty with hemostasis during biopsy or surgery [7, 12, 13, 16, 25, 27, 34, 36, 39]. Three patients underwent preoperative vascular embolization or ligation, which did not lead to complications during surgery [9, 10, 13]. Our experience with the present patient also indicated that preoperative vascular embolization is helpful in preventing massive hemorrhage during biopsy and surgery for pulsatile oral metastasis of RCC. We believe that surgical therapy after vascular embolization can improve or maintain quality of life for the patients with oral metastasis of renal carcinoma, even if they are late stage oncological patients.

Table 3 Summary of the reported cases of renal cell cancer metastasis in the maxillary bone

Case	Age	Gender	Pulsation	Treatment	Outcome		Ref.
					Oral metastasis	Prognosis ^a	
1	66	F	–	S	ND	ND	9
2	58	M	+	E	Uncontrolled	Dead, 2 m	20
3	73	M	+	E	NS	Dead, 1.5 m	20
4	53	F	–	R + E + S	Controlled	Alive, 14 m	26
5	60	M	–	S	ND	ND	52
6	54	M	–	CR	ND	Dead, 11 m	59
7	89	M	+	E + S	Controlled	Dead, 19 m	^b

CR chemoradiotherapy, E embolization, F female, M male, ND not described, NS no symptom with disease, R radiotherapy, S surgery

^a Numbers are length of follow-up in months^b Present case

Conclusions

Although oral metastasis of RCC has a poor prognosis due to the presence of concurrent disseminated metastases, surgical therapy may be recommended because of its high local control rate and ability to maintain quality of life. Preoperative vascular embolization is considered to be effective to reduce intraoperative hemorrhage, which leads to safe operation.

Abbreviation

RCC: Renal cell carcinoma

Acknowledgements

Not applicable.

Authors' contributions

All authors were involved in the preparation of this manuscript. NN and HS designed the report, collected and assembled the data, and edited the manuscript. TO, MY, and YS collected the patient's clinical data. YO, KK, and TI performed the pathological diagnosis. HH provided critical revision and the approval of the manuscript. All authors read and approved the final manuscript.

Funding

Not applicable.

Availability of data and materials

All data generated or analysed during this study are included in this published article.

Ethics approval and consent to participate

All ethical principles were considered in conducting this case report. The patient signed the consent form, and all patient information will be kept confidential.

Consent for publication

Written informed consent was obtained from the patient for publication of this case report and any accompanying images. A copy of the consent form is available for review by the Editor-in-Chief of this journal.

Competing interests

The authors declare that they have no competing interests

Author details

¹Department of Oral and Maxillofacial Surgery, Graduate School of Medical and Dental Sciences, Tokyo Medical and Dental University, 1-5-45 Yushima, Bunkyo-ku, Tokyo 113-8549, Japan. ²Department of Oral Pathology, Graduate School of Medical and Dental Sciences, Tokyo Medical and Dental University, 1-5-45 Yushima, Bunkyo-ku, Tokyo 113-8549, Japan.

Received: 23 August 2020 Accepted: 7 September 2020

Published online: 12 October 2020

References

- Meyer I, Shklar G. Malignant tumors metastatic to mouth and jaws. *Oral Surg Oral Med Oral Pathol.* 1965;20:350–62.
- Calonius PE, Sainio P, Oikarinen VJ. Metastatic tumours to the oral region. II. Report on 13 cases. *Proc Finn Dent Soc.* 1975;71:66–71.
- Makos CP, Psomadakis K. A literature review in renal carcinoma metastasis to the oral mucosa and a new report of an epulis-like metastasis. *J Oral Maxillofac Surg.* 2009;67:653–60.
- Maldazys JD, deKernion JB. Prognostic factors in metastatic renal carcinoma. *J Urol.* 1986;136:376–9.
- Boles R, Cerny J. Head and neck metastases from renal carcinomas. *Mich Med.* 1971;70:616–8.
- Milobsky SA, Milobsky L, Epstein LI. Metastatic renal adenocarcinoma presenting as periapical pathosis in the maxilla. *Oral Surg Oral Med Oral Pathol.* 1975;39:30–3.
- Tani K, Namba K, Teranobu K. Renal carcinoma with metastasis to the mandible. *J Jpn Stomatol Soc.* 1976;25:495–500.
- Sidhu SS, Parkash H, Chopra P. Renal metastatic carcinoma of the mandible. *J Dent.* 1982;10:103–6.
- Lutcavage GJ, Branham GB, Winterholler BW, Wood DA. Renal cell carcinoma metastasis to the hard palate. *J Oral Maxillofac Surg.* 1984;42:469–74.
- Jones GM, Telfer MR, Eveson JW. Metastatic renal clear cell carcinoma of the jaws. Two cases illustrating clinical and pathological diagnostic problems. *Br J Oral Maxillofac Surg.* 1990;28:172–5.
- Ord RA, Malins T, Ward-Booth PR. Vascular metastatic renal carcinoma of the maxilla. Report of two cases. *Int J Oral Maxillofac Surg.* 1990;19:106–9.
- Shiomi Y, Tasaka Y, Kano Y. Metastasis of renal cell carcinoma to lingual ectopic thyroid; a case report. *Jibi Rinsho.* 1992;85:975–9.
- Pritchky KM, Schiff BA, Newkirk KA, Krowiak E, Deeb ZE. Metastatic renal cell carcinoma to the head and neck. *Laryngoscope.* 2002;112:1598–602.
- Makita H, Miyazaki Y, Yamashita T. A case of renal cell carcinoma metastasizing to the buccal mucosa. *Nihon Koku Shindan Gakkai Zasshi.* 2006;19:306–9.
- Langille G, Taylor SM, Bullock MJ. Metastatic renal cell carcinoma to the head and neck: summary of 21 cases. *J Otolaryngol Head Neck Surg.* 2008;37:515–21.
- Nishikawa Y, Sumida T, Murase R, Ishikawa A. A case of renal cell carcinoma detected by a rapid-growing huge mass in the oral cavity. *Nihon Koku Shindan Gakkai Zasshi.* 2010;23:37–42.
- Pires FR, Azevedo RS, Ficarra G, Cardoso AS, Carlos R, Kowalski LP, et al. Metastatic renal cell carcinoma to the oral cavity and clear cell mucoepidermoid carcinoma: comparative clinicopathologic and immunohistochemical study. *Oral Surg Oral Med Oral Pathol Oral Radiol Endod.* 2010;109:e22–7.
- Ganini C, Lasagna A, Ferraris E, Gatti P, Paglino C, Imarisio I, et al. Lingual metastasis from renal cell carcinoma: a case report and literature review. *Rare Tumors.* 2012;4:e41.
- Kelles M, Akarcay M, Kizilay A, Samdanci E. Metastatic renal cell carcinoma to the condyle of the mandible. *J Craniofac Surg.* 2012;23:e302–3.
- Schwab B, Lee WT. Bilateral renal cell carcinoma metastasis in the oral cavity. *Am J Otolaryngol.* 2012;33:154–5.
- Ahmadnia H, Amirmajidi NM, Mansourian E. Renal cell carcinoma presenting as mandibular metastasis. *Saudi J Kidney Dis Transpl.* 2013;24:789–92.
- Matias M, Casa-Nova M, Borges-Costa J, Ribeiro L. Unusual head metastasis of kidney cancer. *BMJ Case Rep.* 2013;2013:bcr2013200004.
- Mazeron R, Fenoll L, Mathieu MC, Dumas I, Haie-Meder C. Brachytherapy for isolated tongue metastasis of renal clear cell carcinoma. *Eur Ann Otorhinolaryngol Head Neck Dis.* 2013;130:149–51.
- Khobragade KH, Bakshi GK, Prakash G, Menon S. Tongue trail to kidney. *Indian J Med Paediatr Oncol.* 2014;35:106–8.
- Nakamura M, Koga M, Harada M. A possible case of metastatic renal cell carcinoma to the mandible 26 years after nephrectomy. *Nihon Koku Geka Gakkai Zasshi.* 2014;60:44–8.
- Yamamoto K, Hirai E, Nishikawa T, Fushimi C. A case of multiple metastatic renal cell carcinoma detected by a tumor of the upper gingiva, and a review of the literature. *Nihon Koku Shindan Gakkai Zasshi.* 2014;27:40–7.
- Zhang L, Yang H, Zhang X. Metastatic renal cell carcinoma to the jaws: report of cases. *World J Surg Oncol.* 2014;12:204.
- Terenzi V, Cassoni A, Zadeh OR, Raponi I, Della Monaca M, Bartoli D, et al. Metastases to oro-maxillo-facial region from distant sites: are they so rare? A single centre 8-years experience. *Ann Ital Chir.* 2015;86:5–8.
- Noi M, Tsuda Y, Saito S. A case of renal cell carcinoma diagnosed in association with a palatal mucosa mass. *Nihon Koku Geka Gakkai Zasshi.* 2016;62:62–6.
- Wang C, Takeda K, Shiba M, Takayama H, Munakata S. Metastasis to the tongue from renal cell carcinoma 10 years after nephrectomy: a case report. *Hinyokika Kyo.* 2016;62:407–10.
- Raiss H, Duplomb S, Tartas S, Layachi M, Errihani H. Lingual metastasis as an initial presentation of renal cell carcinoma: a case report. *J Med Case Rep.* 2017;11:314.
- Derakhshan S, Rahrotaban S, Mahdavi N, Mirjalili F. Metastatic renal cell carcinoma presenting as maxillary lesion: report of two rare cases. *J Oral Maxillofac Pathol.* 2018;22:539–43.

33. Morita Y, Iwagami T, Kawakita C, Kusuyama Y, Niki-Yonekawa A, Morita N. Oral metastasis of renal cell carcinoma mimicking recurrence of excised malignant myoepithelioma: a case report. *Mol Clin Oncol.* 2018;9:66–9.
34. Saito N, Takeuchi G, Asai Y. A case of renal cell carcinoma metastasis to the upper gingiva. *Niigata Dent J.* 2018;48:29–34.
35. Vasilyeva D, Peters SM, Philipone EM, Yoon AJ. Renal cell carcinoma metastatic to the maxillary gingiva: a case report and review of the literature. *J Oral Maxillofac Pathol.* 2018;22:S102–7.
36. Altunsoy E, Göze ÖF, Özeç I. Metastasis of renal cell carcinoma to mandible. *JCR.* 2019; <https://doi.org/10.17659/01.2019.0011>.
37. Netto R, de Freitas Filho SAJ, Cortezzi W, Merly F, de Andrade VM, Pires FR. Metastasis of renal cell carcinoma causing significant facial asymmetry. *Case Rep Surg.* 2019;2019:6840873.
38. Saito D, Abe R, Hino M, Yagi M, Mizuki H, Yamada H. A case of renal cell carcinoma in which long-term survival was obtained by simultaneous surgical resection of the primary tumor and maxillary gingival metastasis. *Nihon Koku Geka Gakkai Zasshi.* 2019;65:172–8.
39. Ludwig DC, Garcia J, Chang OH, Closmann JJ. Metastatic renal cell carcinoma to the mandible: a case report with clinical and histologic findings. *Gen Dent.* 2020;68:41–4.
40. Nisi M, Izzetti R, Graziani F, Gabriele M. Renal cell carcinoma metastases to the oral cavity: report of 2 cases and review of literature. *J Oral Maxillofac Surg.* 2020;78(9):1557–1.
41. Yoshitomi I, Kawasaki G, Mizuno A, Nishikido M, Hayashi T, Fujita S, *et al.* Lingual metastasis as an initial presentation of renal cell carcinoma. *Med Oncol.* 2011;28:1389–94.

Publisher's Note

Springer Nature remains neutral with regard to jurisdictional claims in published maps and institutional affiliations.

Ready to submit your research? Choose BMC and benefit from:

- fast, convenient online submission
- thorough peer review by experienced researchers in your field
- rapid publication on acceptance
- support for research data, including large and complex data types
- gold Open Access which fosters wider collaboration and increased citations
- maximum visibility for your research: over 100M website views per year

At BMC, research is always in progress.

Learn more biomedcentral.com/submissions

