

CASE REPORT

Open Access



Hemophagocytic lymphohistiocytosis in a patient with COVID-19 treated with tocilizumab: a case report

Birgitte Tholin^{1*} , Marit Teigen Hauge^{1,2}, Pål Aukrust^{3,4}, Lutz Fehrle⁵ and Tor Henrik Tvedt⁶

Abstract

Background: The understanding of coronavirus disease 2019 (COVID-19) is rapidly evolving. Although it is primarily a respiratory illness, other manifestations, such as Guillain-Barré syndrome, immune thrombocytopenia, and immune-mediated thrombotic thrombocytopenic purpura, have been described. We present a case of a patient with hemophagocytic lymphohistiocytosis secondary to COVID-19 treated with tocilizumab with a marked biochemical improvement.

Case presentation: In this case report we present a Caucasian patient with COVID-19 who developed a marked elevation of inflammatory parameters with ferritin 36,023 µg/L, but also elevated C-reactive protein 334 mg/L and lactate dehydrogenase 1074 U/L, 1 week after admission to the intensive care unit. He met five of eight criteria for hemophagocytic lymphohistiocytosis, but he lacked the high fever and cytopenia seen in the majority of cases. He was treated with tocilizumab, a monoclonal antibody targeting the interleukin-6 receptor, and over the next days, a rapid decrease in ferritin and C-reactive protein levels was observed. However, his respiratory failure only improved gradually, and he was weaned off the respirator 11 days later.

Conclusion: COVID-19 may induce a hyperinflammatory clinical picture and in some cases develop into hemophagocytic lymphohistiocytosis. In our patient's case, therapeutic interleukin-6 blockade abrogated signs of hyperinflammation but did not seem to improve pulmonary function. Measurement of ferritin and C-reactive protein, as well as quantification of interleukin-6 on indication, should be performed in patients with severe COVID-19. Specific treatment in such patients must also be contemplated, preferably in randomized controlled trials.

Keywords: COVID-19, HLH, Hemophagocytic lymphohistiocytosis, IL-6, Tocilizumab, Case report

Introduction

Severe coronavirus disease 2019 (COVID-19) infection, particularly in those with acute respiratory distress syndrome (ARDS), is characterized by marked inflammation and immune activation with elevated levels of inflammatory cytokines, such as interleukin (IL)-6 and tumor necrosis factor [1]. Significantly elevated levels of ferritin as a marker of extensive macrophage activation have also

been reported [2]. We describe a case of a patient with a marked systemic immune reaction with features of hemophagocytic lymphohistiocytosis (HLH) who was treated with the IL-6 receptor antagonist tocilizumab.

Case presentation

A Caucasian man in his 70s was admitted to his local hospital because of fever, diarrhea, and abdominal pain for the previous 10 days. His past medical history was significant for diverticulosis, and he was also being treated for locally advanced prostate cancer with

* Correspondence: birgitte.tholin@helse-mr.no

¹Department of Internal Medicine, Molde Hospital, Molde, Norway
Full list of author information is available at the end of the article



© The Author(s). 2020 **Open Access** This article is licensed under a Creative Commons Attribution 4.0 International License, which permits use, sharing, adaptation, distribution and reproduction in any medium or format, as long as you give appropriate credit to the original author(s) and the source, provide a link to the Creative Commons licence, and indicate if changes were made. The images or other third party material in this article are included in the article's Creative Commons licence, unless indicated otherwise in a credit line to the material. If material is not included in the article's Creative Commons licence and your intended use is not permitted by statutory regulation or exceeds the permitted use, you will need to obtain permission directly from the copyright holder. To view a copy of this licence, visit <http://creativecommons.org/licenses/by/4.0/>. The Creative Commons Public Domain Dedication waiver (<http://creativecommons.org/publicdomain/zero/1.0/>) applies to the data made available in this article, unless otherwise stated in a credit line to the data.

goserelin and for chronic back pain with prednisolone 2.5 mg once daily.

On admission, his blood pressure was 134/85 mmHg, body temperature was 38.7 °C, heart rate was 87 beats/minute, respiratory rate was 18 breaths/minute, and oxygen saturation was 92% without oxygen support. He was slightly overweight with a body mass index (BMI) of 27 kg/m², but the findings of his physical examination were otherwise normal. His laboratory test values, presented in Table 1, showed elevated C-reactive protein (CRP), thrombocytopenia, and moderately elevated ferritin. Arterial blood gas analysis revealed respiratory alkalosis with hypoxemia and normal lactate. A radiographic examination showed scattered consolidations in the right lung.

The patient had a positive test result for severe acute respiratory syndrome coronavirus 2 (SARS-CoV-2) based on real-time reverse transcriptase polymerase chain reaction of a nasopharyngeal specimen. Empirical treatment with cefotaxime and ciprofloxacin was prescribed for suspected bacterial superinfection as well as an antiviral regime of lopinavir-ritonavir and hydroxychloroquine according to local guidelines at the time.

Twelve hours later, the patient's condition deteriorated, with rapidly progressing respiratory failure, oxygen saturation at 86% on 12-L oxygen, and a respiratory frequency of 40 breaths/minute. This prompted transfer to the intensive care unit (ICU) and intubation. A new chest x-ray revealed extensive bilateral coalescent opacities qualifying as severe ARDS (ratio of arterial oxygen partial pressure to fractional inspired oxygen [FiO₂], ≤ 100 mmHg).

During the first 36 hours in the ICU, the patient was in unstable cardiopulmonary condition. He required high FiO₂ and norepinephrine in moderate doses, and

he developed supraventricular tachyarrhythmia that was treated with repeated electrical and pharmacological cardioversion. By day 7, he had accumulated significant amounts of fluid (positive fluid balance of 8 L). His creatinine levels were rising, and he responded poorly to diuretics. Continuous venovenous hemodiafiltration was initiated to ensure a negative fluid balance.

The antiviral drug regimen was discontinued after 3 days due to a national agreement that all SARS-CoV-2 viral drug treatments should be administered through randomized controlled studies. Due to rising CRP and leukocyte counts, the antibiotics were changed to meropenem.

One week after admission, the patient achieved circulatory stability and exhibited a slowly decreasing oxygen demand, but his ferritin had risen markedly to 36,023 µg/L. This was accompanied by occasional fever and marked increases in CRP (334 mg/L), lactate dehydrogenase (LDH) (1074 U/L), neutrophil count (20.3 × 10⁹/L), and triglycerides (5.27 mmol/L). His triglycerides were analyzed during parenteral nutrition and must be interpreted with caution.

This raised concern that the patient had developed HLH secondary to SARS-CoV-2. His soluble IL-2 receptor level was considerably elevated at 6809 U/ml (> 623 U/ml indicates immune activation and T-cell activation in particular), and a bone marrow smear demonstrated hemophagocytosis. Flow cytometry of peripheral blood showed a significant decrease in circulating CD4⁺ and CD8⁺ T cells (161/µl and 32/µl, respectively) but an expanded population of clonal B cells that expressed kappa, CD5, CD19, CD20 (weakly), CD43, CD45, and CD200. Due to the absence of lymphocytosis, and after a review of laboratory records, this was classified as monoclonal B-cell lymphocytosis (MBL) and not as chronic

Table 1 An overview of relevant laboratory parameters during the clinical course

Parameter	Reference range	Admission Day 0	ICU Day 2	Day 5	Day 6	Day 7	Day 8	Extubation Day 18
Hemoglobin (g/dl)	13.7–16.5	12.9	11.7	11.3	11.8	11.1	11.3	8.8
Neutrophils (10 ⁹ /L)	1.5–5.7	6.6	–	–	20.3	31.3	30.5	8.0
Lymphocytes (10 ⁹ /L)	1.3–3.4	1.6	–	–	–	–	–	–
Platelet count (10 ⁹ /L)	145–390	95	107	179	197	190	177	222
Creatinine (mg/dl)	60–105	115	91	297	339	233	155	156
CRP (mg/L)	0–4	167	224	315	348	276	63	12
Ferritin (µg/L)	23–431	544	635	6399	36,023	75,920	20,730	625
Bilirubin (µmol/L)	5–25	8	7	32	39	47	60	10
LD (U/L)	115–255	522	583	–	1074	1559	973	438
Fibrinogen (g/L)	2–4	–	–	–	6.5	5.9	–	–
Triglyceride (mmol/L)	0.45–2.60	–	–	–	5.27	5.71	–	–

Abbreviations: CRP C-reactive protein, ICU Intensive care unit, LDH Lactate dehydrogenase

lymphocytic leukemia (CLL), which requires >5000 cells/ μl . A trephine biopsy confirmed MBL but no other lymphoproliferative disorders.

The patient fulfilled five of eight HLH-2004 diagnostic criteria, and his H-score estimated the probability of HLH to be 96–98% [3, 4]. A decision was made to give the patient tocilizumab 800 mg intravenously, a monoclonal antibody against the IL-6 receptor that is used when cytokine release syndrome (CRS) is seen following the infusion of chimeric antigen receptor T cells.

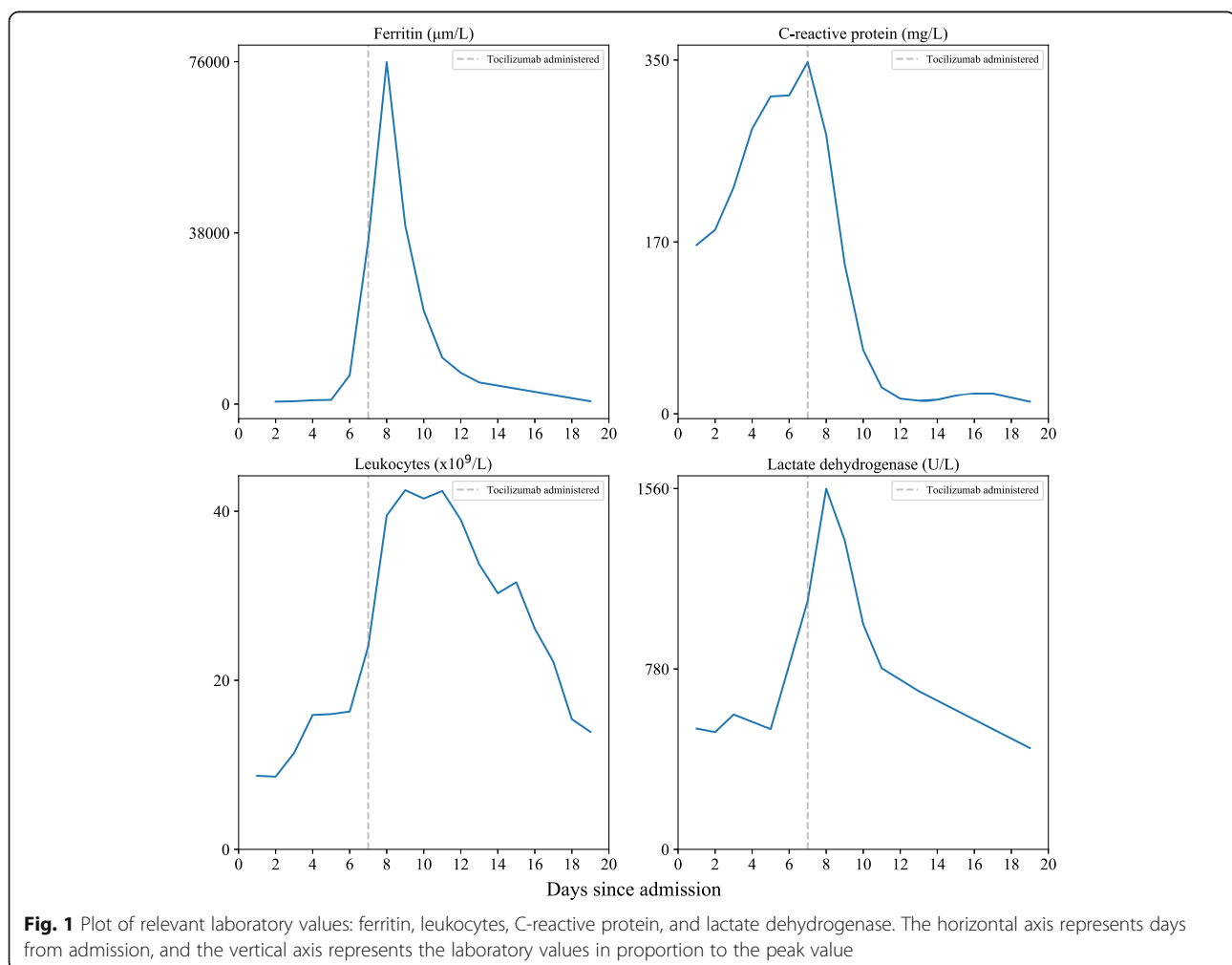
The following day, the patient's CRP declined rapidly, followed by a significant but slow decline in ferritin and LDH levels (Table 1, Fig. 1). After the administration of tocilizumab, no fever was observed. Three days later, the patient also received one dose of intravenous immunoglobulins pending the result of protein electrophoresis, which was normal. His clinical state improved 5–7 days later, and he was successfully extubated.

After the patient's improvement, we analyzed serum levels of selected cytokines on the same day as tocilizumab was given (samples taken before administration)

by enzyme-linked immunosorbent assay. Interestingly, his IL-6 levels were markedly elevated at 84 pg/ml (<5 pg/ml), whereas TNF and IL-10 were moderately elevated at 55 pg/ml (<20 pg/ml) and 38 pg/ml (<5 pg/ml), respectively. His IL-8 (66 pg/ml) and IL-1 β (<5 pg/ml) were within the normal range of the laboratory that did the tests (Sahlgrenska University Hospital, Gothenburg, Sweden).

Discussion and conclusions

We report a case of a patient with marked immune activation accompanied by ARDS with a biochemical pattern consistent with secondary HLH who responded biochemically after one dose of the IL-6 receptor antagonist tocilizumab. HLH is characterized by hyperinflammation; fever; multiorgan involvement; and, in severe cases, marked hemophagocytosis with cytopenia. Although primary HLH is caused by genetic defects that impair natural killer (NK) or T-cell function, secondary HLH is caused by various disorders, most commonly malignancies, infections, and autoimmune disorders. HLH is diagnosed either by detection of HLH-associated



mutations (diagnostic for primary HLH) or by verification of a minimum of five of the following eight criteria: fever >38.5 °C, splenomegaly, cytopenia, fasting hypertriglyceridemia (>265 mg/dl) and/or hypofibrinogenemia (<150 mg/dl), hemophagocytosis, low or absent NK cell activity, ferritin >500 ng/ml, and soluble IL-2-receptor elevated 2 SD above age-adjusted laboratory-specific norms. Macrophage activation syndrome (MAS) shares some feature of HLH, such as strong macrophage activation and excessive hyperferritinemia. MAS is associated with autoimmune diseases, especially juvenile idiopathic arthritis, systemic lupus erythematosus, Kawasaki disease, and juvenile dermatomyositis [5].

Both primary and secondary HLH can be triggered by viral infections, Epstein-Barr virus infection in particular [6]. There are several reports of cytokine “storm” or hyperinflammation in patients with COVID-19 with elevated levels of several inflammatory cytokines, but in most of these cases, there are no other signs of HLH, and the ferritin level is seldom $>35,000$ $\mu\text{g/L}$ as in our patient’s case [1, 7]. The mechanisms of this SARS-CoV-2-triggered “immune storm” that can develop into HLH are currently unclear, but several not mutually exclusive mechanisms could be operating. *In vitro* studies have suggested that SARS-CoV-2 could activate NLRP3 inflammasomes that are potent activators of macrophages, with a marked release of IL-1 β as a consequence, which subsequently contributes to IL-6 release [8]. Furthermore, molecular docking analysis predicts spontaneous interaction between the spike glycoprotein of SARS-CoV-2 and Toll-like receptors 5 (TLR5). TLR5 is expressed on monocytes and significantly contributes to IL-6 release thorough activation of nuclear factor- κB activation [9]. Moreover, through downregulation of the angiotensin (AT)-converting enzyme 2, the putative SARS-CoV-2 receptor, the virus could induce a downregulation of the antiproliferative and anti-inflammatory AT-1-7 pathway [10].

Infection with SARS-CoV-2 induces a great variety of clinical symptoms, ranging from asymptomatic to mild or critical. Although severe illness can occur in otherwise healthy individuals of all ages, it predominantly occurs in individuals older than 65 years of age [11]. One factor associated with a severe course of SARS-CoV-2 infection is impaired or delayed T-cell response [12]. Interestingly, we were able to verify the presence of clonal B cells with the CLL immunophenotype in our patient. Due to the low number of circulating lymphocytes, the condition was characterized as MBL. Clonal lymphocytosis occurs in $<0.5\%$ of the population under the age of 40 but increases significantly with age and can be demonstrated in 10–20% of individuals over 70 years old, increasing even more with age [13]. MBL increases susceptibility to viral infections through several

mechanisms, including hypogammaglobulinemia, the accumulation of incompetent lymphocytes with an impaired response to immunological stimuli, and a reduced cytotoxic capacity of CD8⁺ cells due to reduced granzyme levels and the nonpolarized degranulation of vesicles [14]. Furthermore, it is well known that the immune dysfunction in some patients with CLL can result in HLH [15].

Other possible influencing factors in our patient were prolonged obesity, treatment with low-dose steroid, and medical castration with goserelin. Goserelin has not been reported to have immunological side effects but is associated with a weight increase in approximately 5% of patients. This, in addition to steroids, could have contributed to his raised BMI which is a recognized risk factor for developing severe COVID-19. Whether these factors influenced the clinical course in our patient is speculative.

Secondary HLH, MAS, and CRS constitute a heterogeneous group of conditions that are all characterized by macrophage activation and excessive cytokine production, and IL-6 seems to be involved in various degrees in all these conditions. Such mechanisms could also be operating in severe COVID-19 infection. Thus, there are some reports of beneficial effects of tocilizumab in severe COVID-19, and randomized studies are ongoing [16]. Our patient had markedly elevated IL-6 levels and a profound and rapid decline in CRP as a biomarker of IL-6 activity, further supporting a role for IL-6-driven inflammation in severe COVID-19 infection. Notably, whereas there was a rapid decline in CRP, there was an incidental increase in ferritin following administration of tocilizumab before a significant decline, suggesting that the effect of tocilizumab on macrophage activation involves secondary effects of IL-6. An early and significant rise in IL-6 levels during SARS-CoV-2 infections is associated with a poor outcome. One should consider screening with ferritin and CRP in cases of severe COVID-19 with apparent hyperinflammation, particularly because CRP is known to be an indirect marker of IL-6 [17]. With significantly elevated levels, the diagnosis could be further supported by quantitating IL-6.

Acknowledgements

None.

Authors’ contributions

All authors contributed to the writing and revision of the manuscript. BT and THT were responsible for the final version of the manuscript. All authors read and approved the final manuscript.

Funding

None.

Availability of data and materials

NA.

Ethics approval and consent to participate

Approval from an ethics committee was not required according to national policy. Patient consent has been obtained and can be displayed upon request.

Consent for publication

Written informed consent was obtained from the patient for publication of this case report and any accompanying images. A copy of the written consent is available for review by the Editor-in-Chief of this journal.

Competing interests

The authors declare that they have no competing interests.

Author details

¹Department of Internal Medicine, Molde Hospital, Molde, Norway.

²Department of Microbiology, Molde Hospital, Molde, Norway. ³Research Institute of Internal Medicine, Oslo University Hospital and University of Oslo, Oslo, Norway. ⁴Section of Clinical Immunology and Infectious Diseases, Oslo University Hospital, Oslo, Norway. ⁵Department of Anesthesiology, Molde Hospital, Molde, Norway. ⁶Section of Hematology, Department of Internal Medicine, Haukeland University Hospital, Bergen, Norway.

Received: 8 May 2020 Accepted: 17 August 2020

Published online: 15 October 2020

References

- Mehta P, McAuley DF, Brown M, *et al.* COVID-19: consider cytokine storm syndromes and immunosuppression. *Lancet*. 2020;395:1033–4.
- Lambotte O, Cacoub P, Costedoat N, Le Moel G, Amoura Z, Piette JC. High ferritin and low glycosylated ferritin may also be a marker of excessive macrophage activation. *J Rheumatol*. 2003;30(5):1027–8.
- Jordan MB, Allen CE, Weitzman S, Filipovich AH, McClain KL. How I treat hemophagocytic lymphohistiocytosis. *Blood*. 2011;118(15):4041–52.
- Debaugnies F, Mahadeb B, Ferster A, *et al.* Performances of the H-score for diagnosis of hemophagocytic lymphohistiocytosis in adult and pediatric patients. *Am J Clin Pathol*. 2016;145(6):862–70.
- Lin CI, Yu HH, Lee JH, *et al.* Clinical analysis of macrophage activation syndrome in pediatric patients with autoimmune diseases. *Clin Rheumatol*. 2012;31(8):1223–30.
- Filipovich A, McClain K, Grom A. Histiocytic disorders: recent insights into pathophysiology and practical guidelines. *Biol Blood Marrow Transplant*. 2010;16(1 Suppl):S82–9.
- Zhang C, Wu Z, Li JW, Zhao H, Wang GQ. Cytokine release syndrome in severe COVID-19: interleukin-6 receptor antagonist tocilizumab may be the key to reduce mortality. *Int J Antimicrob Agents*. 2020;55(5):105954.
- Zhao C, Zhao W. NLRP3 inflammasome—a key player in antiviral responses. *Front Immunol*. 2020;11:211.
- Bhattacharya M, Sharma AR, Patra P, *et al.* Development of epitope-based peptide vaccine against novel coronavirus 2019 (SARS-COV-2): immunoinformatics approach. *J Med Virol*. 2020;92(6):618–31.
- Tignanelli CJ, Ingraham NE, Sparks MA, *et al.* Antihypertensive drugs and risk of COVID-19? *Lancet Respir Med*. 2020;8(5):e30–1.
- Epidemiology Working Group for NCIP Epidemic Response, Chinese Center for Disease Control and Prevention. The epidemiological characteristics of an outbreak of 2019 novel coronavirus diseases (COVID-19) in China [in Chinese]. *Zhonghua Liu Xing Bing Xue Za Zhi*. 2020;41(2):145–51.
- Zheng HY, Zhang M, Yang CX, *et al.* Elevated exhaustion levels and reduced functional diversity of T cells in peripheral blood may predict severe progression in COVID-19 patients. *Cell Mol Immunol*. 2020;17(5):541–3. <https://doi.org/10.1038/s41423-020-0401-3>.
- Strati P, Shanafelt TD. Monoclonal B-cell lymphocytosis and early-stage chronic lymphocytic leukemia: diagnosis, natural history, and risk stratification. *Blood*. 2015;126(4):454–62.
- Lanasa MC, Weinberg JB. Immunologic aspects of monoclonal B-cell lymphocytosis. *Immunol Res*. 2011;49(1–3):269–80.
- Bailey C, Dearden C, Ardeshta K. Haemophagocytic lymphohistiocytosis as a consequence of untreated B-cell chronic lymphocytic leukaemia. *BMJ Case Rep*. 2017;2017:bcr2016219057.
- Xu X, Han M, Li T, *et al.* Effective treatment of severe COVID-19 patients with tocilizumab. *Proc Natl Acad Sci U S A*. 2020;117(20):10970–10975. <https://doi.org/10.1073/pnas.2005615117>.
- Del Giudice M, Gangestad SW. Rethinking IL-6 and CRP: Why they are more than inflammatory biomarkers, and why it matters. *Brain Behav Immun*. 2018;70:61–75.

Publisher's Note

Springer Nature remains neutral with regard to jurisdictional claims in published maps and institutional affiliations.

Ready to submit your research? Choose BMC and benefit from:

- fast, convenient online submission
- thorough peer review by experienced researchers in your field
- rapid publication on acceptance
- support for research data, including large and complex data types
- gold Open Access which fosters wider collaboration and increased citations
- maximum visibility for your research: over 100M website views per year

At BMC, research is always in progress.

Learn more biomedcentral.com/submissions

