

Case report

Open Access

The first case of vesico-vaginal fistula in a patient with primary lymphoma of the bladder – a case report

David A Evans* and Andrew T Moore

Address: Kings Mill Hospital, Mansfield Road, Sutton-In-Ashfield, Nottinghamshire, NG17 4JT, UK

Email: David A Evans* - daveevans@doctors.net.uk; Andrew T Moore - andy.moore@doctors.net.uk

* Corresponding author

Published: 27 September 2007

Received: 10 April 2007

Journal of Medical Case Reports 2007, 1:105 doi:10.1186/1752-1947-1-105

Accepted: 27 September 2007

This article is available from: <http://www.jmedicalcasereports.com/content/1/1/105>

© 2007 Evans and Moore; licensee BioMed Central Ltd.

This is an Open Access article distributed under the terms of the Creative Commons Attribution License (<http://creativecommons.org/licenses/by/2.0>), which permits unrestricted use, distribution, and reproduction in any medium, provided the original work is properly cited.

Abstract

Background: Primary lymphoma of the bladder is a rare condition with less than 100 cases reported in the literature.

Case presentation: Here we present the case of a 64 year old woman with a 9 month history of haematuria, frequency, urinary incontinence and weight loss. Cystoscopy revealed a solid tumour throughout the whole bladder wall and a vesico-vaginal fistula. This was confirmed on CT scan which also showed no other organ involvement and bilateral hydronephrosis. Trans urethral biopsies taken at cystoscopy revealed Non-Hodgkin's Lymphoma. The patient had a nephrostomy inserted and is currently receiving a course of chemotherapy.

Conclusion: We believe this is the first documented case of primary bladder lymphoma causing a fistula and therefore we suggest that lymphoma should be included in the differential for any patient with a fistula involving the bladder.

Background

Non-epithelial tumours of the bladder are extremely rare. The most common amongst these are rhabdomyosarcomas in children and leiomyosarcomas in adults[1]. Primary lymphoma of the bladder is even less common accounting for 0.2% of all bladder neoplasms[2]. The most common site of primary extranodal malignant lymphoma is the stomach, followed by connective tissues and skin[3].

Primary lymphoma of the bladder was first described by Eve in 1885[4] and to date less than 100 cases have been reported in the literature[1,5]. Most lymphomas of the bladder are low grade Non-Hodgkin's lymphomas of the B-cell type[1,6]. Amongst the high grade subtypes of bladder lymphoma, diffuse large cell lymphoma is the commonest[7].

Considerable debate remains as to the origin of primary bladder lymphoma. This is largely because normal bladder microscopic sections fail to reveal routinely the presence of lymphoid follicles[8]. A popular theory is that lymphoma follows chronic cystitis, when there is an associated increase in the amount of lymphoid tissue found in the lamina propria[2,3,8,9]. A number of cases have been reported with absence of chronic cystitis and here it is postulated that the tumour may originate in the lymphoid tissue derived from the embryonic cloaca[8].

Lymphoma of the bladder is more common in women[2,3]. The most frequent presenting complaint is gross haematuria, occurring in 81.3% of reported cases. In 46.9%, a concomitant urinary tract infection is present. Dysuria and frequency are the only presenting symptoms in 18.7%[10]. Hydronephrosis is uncommon as the

tumour does not typically involve the ureteric orifices. Involvement of the entire bladder wall is also a rare phenomenon[11-13].

Case presentation

A 64 year old woman presented to our outpatients clinic with a 9 month history of painless haematuria, frequency and urinary incontinence. On further questioning she admitted to suffering from night sweats and 3 stones of weight loss over the past year. She had been repeatedly treated for urinary tract infections by her general practitioner. There was no other past medical history apart from abdominal hysterectomy.

There was nothing abnormal to find on physical examination of the abdomen or other systems. The urea and electrolytes were normal as was the patient's peripheral blood film.

An abdominal ultrasound scan revealed bilateral hydronephrosis, a large solid pelvic mass with the dimensions 70 mm × 72 mm × 70 mm and no visible bladder despite attempts to fill with water. Cystoscopy showed solid tumor throughout the entire bladder with minimal lumen and a vaginal fistula. This was confirmed by a CT and showed a diffuse 30 mm circumferential thickening of bladder (see figure 1). There was no further lymphadenopathy apparent on CT.

Trans-urethral biopsies taken at cystoscopy revealed the tumour to be a diffuse Large and B Cell Non-Hodgkin's Lymphoma. A bone marrow biopsy revealed normal architecture and cell content.

The patient underwent insertion of a left nephrostomy tube under ultrasound guidance to improve renal function as a preparation for chemotherapy. She then received a course of R-CHOP (Cyclophosphamide, Doxyrubicin, Vincristine, Prednisolone and Ritoximab) chemotherapy. Four months later a repeat CT showed that changes in the region of the bladder were less marked (see figure 2). There was still right sided hydronephrosis and a nephrostomy on the left. The patient, symptomatically improved, remains under the care of the haematologists.

Conclusion

The diagnosis of primary bladder lymphoma was made after excluding a systemic haematological malignancy. Physical examination was normal; specifically there were no palpable lymph nodes and no organomegaly. No further lymphadenopathy was identified on abdominal or chest CT. The peripheral blood film and bone marrow biopsy were normal. This was in keeping with cases described in the literature[13-15].

This case demonstrates many of the commonly recognised features of this rare bladder tumour. Our patient was female, had a past medical history of chronic cystitis, presented initially with dysuria and haematuria and was ultimately shown to have a diffuse large cell lymphoma. It has been proposed that the higher incidence of urinary tract infection may be partly responsible for the higher frequency of bladder lymphoma in women. What is unique about this patient is that as far as we are aware this is the first documented case of a primary bladder lymphoma associated with a vesico-vaginal fistula.

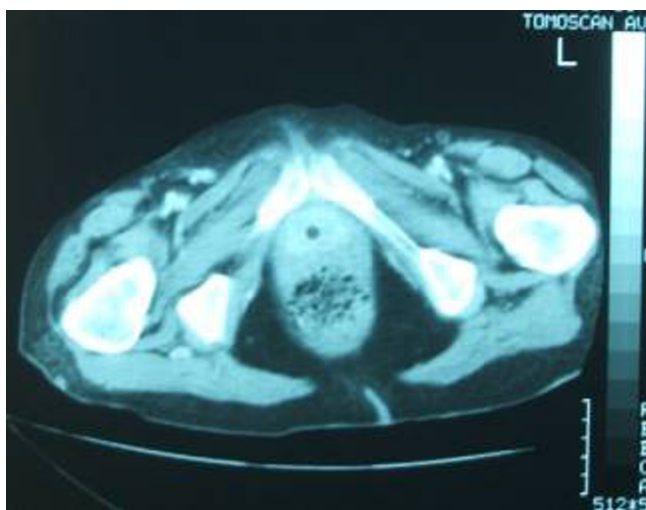


Figure 1
CT image showing thickened bladder wall with minimal lumen.

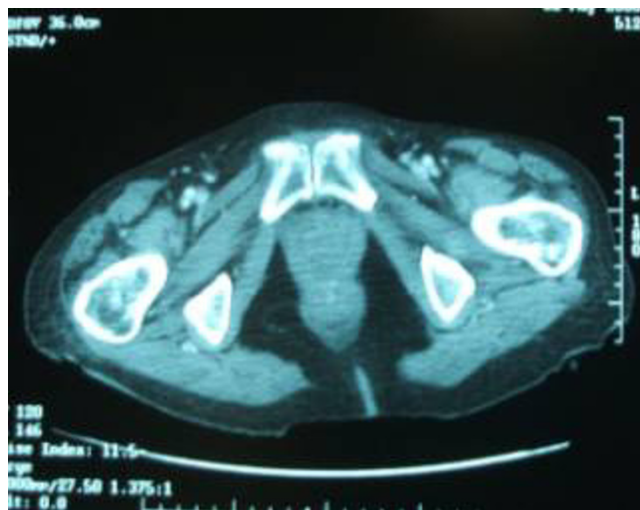

Figure 2
CT post chemotherapy showing relatively normal pelvic architecture.

We suggest that primary bladder lymphoma should be included in a differential for vesico-vaginal fistula. Conversely if a lymphoma is identified we suggest it would be pertinent to exclude a fistula.

Competing interests

The author(s) declare that they have no competing interests.

References

1. Mourad W, Khalil S, Radwi A, Peracha A, Ezzat A: '**Primary T-Cell Lymphoma of the Urinary Bladder**'. *The American Journal of Surgical Pathology* 1998, **22(3)**:373-377.
2. Kuhara H, Tamura Z, Suchi T, Hattori R, Kinukawa T: '**Primary malignant lymphoma of the urinary bladder. A case report**'. *Acta Pathologica Japonica* 1990, **40(10)**:764-769.
3. Freeman C, Berg JW, Cutler SJ: '**Occurrence and prognosis of extranodal lymphomas**'. *Cancer* 1972, **29**:252.
4. Jacobs A, Symington T: '**Primary lymphosarcoma of urinary bladder**'. *Brit J Urol* 1953, **25**:119-125.
5. Wells W: '**Primary low-grade B-cell lymphoma of mucosa-associated lymphoid tissue type arising in the urinary bladder**'. *Arch Pathol Lab Med* 2001, **125**:332-336.
6. Fernandez Acenero MJ, Martin Rodilla C, Lopez Garcia-Asenjo J, Coca Menchero S, Sanz Esponera J: '**Primary Malignant Lymphoma of the Bladder – Report of three cases**'. *Path Res Pract* 1996, **192**:160-163.
7. Melekos MD, Matsouka P, Fokaefs E, Pantazakos A, Repanti M: '**Primary Non-Hodgkin's Lymphoma of the Urinary Bladder**'. *Eur Urol* 1992, **21**:85-88.
8. Aigen A, Phillips M: '**Primary Malignant Lymphoma of Urinary Bladder**'. *Urology* 1986, **28(3)**:235-237.
9. De Bruyne R, Peters O, Goossens A, Braeckman J, Denis LJ: '**Primary IgG-lambda immunocytoma of the urinary bladder**'. *European Journal of Surgical Oncology* 1987, **13**:361-364.
10. Santino AM, Shumaker EJ, Garces J: '**Primary Malignant Lymphoma of the Bladder**'. *The Journal of Urology* 1970, **103**:310-313.
11. Arda K, Ozdemir G, Güneş Z, Ozdemir H: '**Primary malignant lymphoma of the bladder. A case report and review of the literature**'. *International Urology and Nephrology* 1997, **29(3)**:319-322.
12. Bhansali SK, Cameron KM: '**Primary Malignant Lymphoma of the Bladder**'. *British Journal of Urology* 1960, **32**:440.
13. Sharma A, Singh AB: '**Primary Lymphoma Of Urinary Bladder: Report Of An Unusual Case And Literature Review**'. *The Internet Journal of Urology* 2002, **1(1)**.
14. Guthman DA, Malek RS, Chapman WR, Farrow GM: '**Primary Malignant Lymphoma of the Bladder**'. *The Journal of Urology* 1990, **144**:1367-1369.
15. Pontius EE, Nourse MH, Paz L, McCallum DC: '**Primary Malignant Lymphomas of the Bladder**'. *The Journal of Urology* 1963, **90(1)**:58-61.

Publish with **BioMed Central** and every scientist can read your work free of charge

"BioMed Central will be the most significant development for disseminating the results of biomedical research in our lifetime."

Sir Paul Nurse, Cancer Research UK

Your research papers will be:

- available free of charge to the entire biomedical community
- peer reviewed and published immediately upon acceptance
- cited in PubMed and archived on PubMed Central
- yours — you keep the copyright

Submit your manuscript here:
http://www.biomedcentral.com/info/publishing_adv.asp

