

Case report

Open Access

Reconstruction of the urethra with a Surgisis® onlay patch in urethral reconstructive surgery: two case reports

Thorsten H. Ecke^{1*}, Steffen Hallmann¹, Holger Gerullis² and Jürgen Ruttloff¹

Addresses: ¹Department of Urology, HELIOS Hospital, Pieskower Strasse, Bad Saarow 15526, Germany and ²Department of Urology, Lukas Hospital, Preussenstrasse, Neuss 41464, Germany

Email: TH* - tho_ecke@hotmail.com; SH - steffen.hallmann@helios-kliniken.de; HG - holger.gerullis@gmx.net; JR - juergen.ruttloff@helios-kliniken.de

* Corresponding author

Published: 16 March 2009

Received: 4 August 2008

Journal of Medical Case Reports 2009, **3**:7232 doi: 10.1186/1752-1947-3-7232

Accepted: 3 January 2009

This article is available from: <http://jmedicalcasereports.com/jmedicalcasereports/article/view/3/3/7232>

© 2009 Ecke et al; licensee Cases Network Ltd.

This is an Open Access article distributed under the terms of the Creative Commons Attribution License (<http://creativecommons.org/licenses/by/3.0>), which permits unrestricted use, distribution, and reproduction in any medium, provided the original work is properly cited.

Abstract

Introduction: We present two case reports of patients with recurrent stricture of the urethra. We used Surgisis® for reconstruction.

Case presentation: In these two case reports, we show the positive results of reconstructive surgery with Surgisis® as an alternative surgical approach to common onlay patch surgery of the urethra performed on two Caucasian patients: a 48-year-old man and a 55-year-old man.

Conclusion: Compared to buccal mucosa flap or foreskin graft surgeries for urethral reconstruction, reconstructive surgery with Surgisis® is considered a relevant therapeutic alternative because of the shorter operation time and the preventable surgery of the buccal cavity or foreskin.

Introduction

Urethral strictures are defined as restrictions of the urethral lumen irrespective of length and localization. Independent of its origin, diagnosis and treatment of a urethral stricture should be carried out as early as possible in order to avoid irreversible long-term damage [1–2].

Every process affecting the urethral urothelium and the covered tissue of the cavernous body may induce scarring, which can cause urethral stricture. Internal urethrotomy using the Sachse technique is a well established surgical approach for treatment of primary strictures.

Particularly for recurrent or long-segment strictures, open surgical approaches should be preferred because of the known lower relapse rate [2–4]. Widespread applications are in use for autologous transplants, such as urethroplasty with buccal mucosal free grafts [4,5]. Using biodegradable grafts is an excellent solution in this context. In animal studies, the experimental use of small intestinal submucosa (SIS) for reconstruction in the urinary tract has shown promising results [6,7]. The SIS is a collagen-based, nonimmunogenic material obtained from the submucosal layer of a pig's small bowel [5].

We report an alternative to urethroplasty with buccal mucosal free grafts, namely, open surgery urethral reconstruction using porcine small intestine submucosa (Surgisis®) as an onlay patch [8,9].

Case presentation

Case 1: A 48-year-old Caucasian man presented to our institution in February 2004 with a short-segment bulbar urethral stricture. No previous history of trauma or sexually transmitted disease was reported at the time of presentation.

We initially performed urethrotomy using the Sachse technique without complications. Two years later, the patient complained again of decreasing urine stream and frequency.

As shown in Figure 1A, maximal flow was 9.1ml/sec (micturition volume 518ml, micturition time 88 seconds).

Retrograde urethrography revealed a recurrent urethral stricture, as shown in Figure 2A.

Case 2: Thirty-eight years before presentation, this 55-year-old Caucasian man had undergone an open urethral reconstruction after traumatic urethral damage. A recurrent stricture was treated with urethrotomy using a laser technique in 2006. A secondary recurrent urethral stricture developed during short-term follow up, as shown in Figure 3A.

Uroflowmetry revealed a maximal flow of 5.9 ml/second (micturition volume 489 ml, micturition time 120.6 seconds).

In both patients, open surgery urethral reconstruction using Surgisis® as onlay patch was performed in the

dorsosacral position. The urethra was exposed and incised. We identified a 3 cm long stricture in our first patient, and a 4 cm long stricture in our second patient.

End-to-end anastomosis of the urethra was not possible in either case. After incision of the urethra 0.5 cm distally and proximally of the respective stricture, a Surgisis® patch was cut and inserted, in the same way as a buccal mucosal free graft would be inserted, using a 5 × 0 monofil thread with longitudinal splines, over a 16-Foley catheter.

The procedure included insertion of a suprapubic cystostomy. The operation time was 144 minutes for the first patient. Because of the complicated preparation, operation time was 162 minutes for the second patient. No perioperative complications were seen in either case. The transurethral catheter was removed in both patients on day seven postoperatively, and both patients were treated with ciprofloxacin 2 × 500 mg postoperatively for eight days.

On day 24 after the operation, retrograde urethrography revealed good healing in both patients (Figures 2B and 3B). The percutaneous cystostomy catheter was removed on day 25 in both patients.

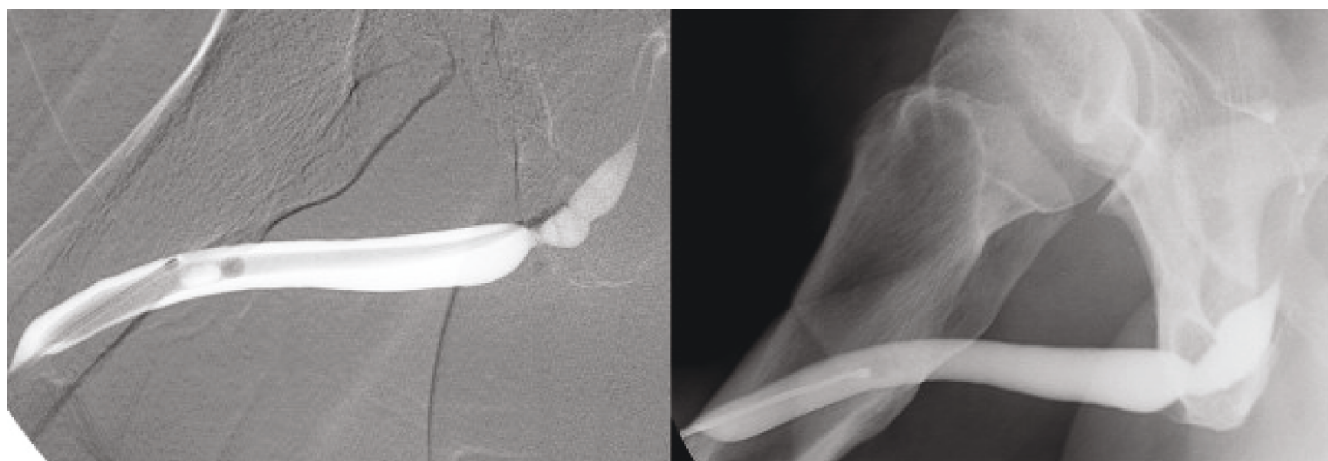
Postoperative uroflowmetry performed on the first patient on day 25 revealed a maximal uroflow of 49.1ml/sec (micturition volume 539 ml, micturition time 21.4 seconds), as shown in Figure 1B. The same procedure performed on the second patient showed a maximal uroflow of 20.6ml/second (micturition volume 563 ml, micturition time 64 seconds), as shown in Figure 1B.

Discussion

The choice of the appropriate material for reconstruction of the male urethra remains a focus of controversy



Figure 1.
(A) and (B) Uroflowmetry before and after reconstruction (case 1).

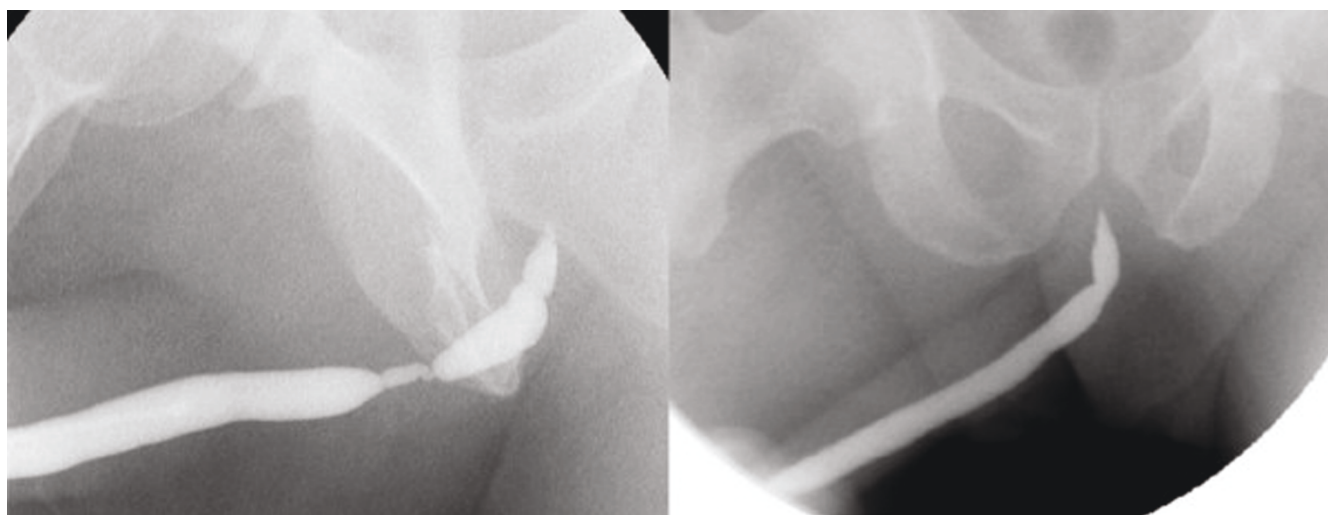
**Figures 2.**

(A) and **(B)** Retrograde urethrography before and after reconstruction (case 1).

[2,4,5,8,9]. Numerous surgical techniques have been previously described, and various types of autologous materials have been used in order to bridge urethral defects [1]. In some cases, the search for new applicable materials became mandatory because of the morbidity associated with classical approaches and the deficiency of available well-vascularized autologous tissues for urethral reconstruction [8,9]. The Surgisis® (by Cook Inc, Spencer, Indianapolis, USA) technique described here could be an interesting surgical alternative for recurrent strictures after previous open urethral surgery. This is one of the first reports in the medical literature of urethral surgery using Surgisis®.

Besides the use of Surgisis® in urethral reconstruction in rabbits with good results [5], synthetic grafts of silicone rubber, siliconized Dacron and Gore-Tex® have also been used for urethral reconstruction in animal experiments, but with poor results. Their use has been associated with a high incidence of infection, calcification and fistula formation [10].

Neither of our patients showed a significant lower flow after a median follow-up time of 22 months, and no further operation was necessary in either case. Neither patient showed complications of infection, allergic reaction, calcification or fistula. Furthermore, we found no

**Figures 3.**

(A) and **(B)** Retrograde urethrography before and after reconstruction (case 2).

probable atrophy of the newly applied tissue, and no recurrent urethral stricture was found.

Biodegradable grafts seem to be an ideal solution for the repair of the urethra as well as other segments of the urinary tract. SIS acts like a framework for the host-tissue cells to migrate and regenerate the organ, both in shape and in function [6,7]. We use Surgisis® to cover urethral defects. Calculating one minute of operation to cost around 15€ and the Surgisis® material used to cost around 280€, we believe that saving over 30 minutes of operation time will more than pay for the cost of use of the Surgisis® material [11].

Although the use of Surgisis® in urethral surgery is an interesting alternative to buccal mucosa flap or foreskin graft surgeries, further studies are needed to evaluate the value of this new technique. Comparison of implantation techniques, position of the graft, antibiotic prophylaxis, catheterization time and long-term outcome need to be documented. Until studies with Surgisis® have demonstrated superiority in efficacy and absence of side effects, buccal mucosa flap or foreskin graft surgery remain the first choices of treatment in patients with long bulbar or penile strictures [1–3,8].

Conclusions

Application of the commercially provided implant system Surgisis® appears to be a reasonable alternative to buccal mucosa flap or foreskin graft surgery in urethral reconstructive surgery. An important advantage of Surgisis® is the prevention of the additional surgery needed in order to obtain a buccal mucosa or foreskin graft. Thus post-operative morbidity and overall surgery time decrease.

Competing interests

The authors declare that they have no competing interests.

Abbreviations

SIS, small intestinal submucosa.

Consent

Written informed consent was obtained from the patients for publication of these case reports and any accompanying images. A copy of the written consent is available for review by the Editor-in-Chief of this journal.

Author's contributions

TH was involved in drafting the manuscript and in the review of the literature and in performing the clinical follow-up. HG was involved in drafting the manuscript and in the review of the literature. SH participated in the surgery and was involved in the clinical follow-up. JR participated in the surgery, was involved in the clinical follow-up and supervised this report. All authors read and approved the final draft.

References

- Andrich DE, Mundy AR: **Substitution urethroplasty with buccal mucosal free grafts.** *J Urol* 2001, **165**:1131-1134.
- Filipas D, Fisch M, Fichtner J, Fitzpatrick J, Berg K, Störkel S, Hohenfellner R, Thüroff JW: **The histology and immunohistochemistry of free buccal mucosa and full-skin grafts after exposure to urine.** *Br J Urol* 1999, **84**:108-111.
- Kessler TM, Schreiter F, Kralidis G, Heitz M, Olinas R, Fisch M: **Long-term results of surgery for urethral stricture: a statistical analysis.** *J Urol* 2003, **170**:840-844.
- Kropp BP, Ludlow JK, Spicer D, Rippey MK, Badylak SF, Adams MC, Keating MA, Rink RC, Birhle R, Thor KB: **Rabbit urethral regeneration using small intestinal submucosa onlay grafts.** *Urology* 1998, **52**:138-142.
- Rotariu P, Yohannes P, Alexianu M, Gershbaum D, Pinkashov D, Morgenstern N, Smith AD: **Reconstruction of Rabbit Urethra with Surgisis® Small Intestinal Submucosa.** *J Endourol* 2002, **16** (Suppl 8):617-20.
- Kropp BP, Eppley BL, Prevel CD, Rippey MK, Harruff RC, Badylak SF, Adams MC, Rink RC, Keating MA: **Experimental assessment of small intestine submucosa as a bladder wall substitute.** *Urology* 1995, **46** (Suppl 3):396-400.
- Lantz GC, Badylak SF, Hiles MC, Coffey AC, Geddes LA, Kokini K, Sandusky GE, Morff RJ: **Small intestine submucosa as a vascular graft: a review.** *J Invest Surg* 1993, **6** (Suppl 3):297-310.
- Schlossberg SM: **A current overview of the treatment of urethral strictures: etiology, epidemiology, pathophysiology, classification, and principles of repair.** In *Reconstructive urethral surgery*. Edited by Schreiter F, Jordan GH. Berlin: Springer; 2006: 60-65.
- Witthuhn R, Persson-de Geeter C, De Geeter P, Löhmer H, Albers P: **Urethrale Reconstruction unter Einsatz eines SIS Onlay-Patches (Surgisis®).** *Urologe* 2006, **45** (Suppl. 1):S44.
- Anwar H, Dave B, Seebode JJ: **Replacement of partially resected canine urethra by polytetrafluorethylene.** *Urology* 1984, **24**:583.
- Dexter F, Blake JT, Penning DH, Sloan B, Chung P, Lubarsky DA: **Use of linear programming to estimate impact of changes in a hospital's operating room time allocation on perioperative variable costs.** *Anesthesiology* 2002, **96** (Suppl 3):718-724.

Do you have a case to share?

Submit your case report today

- Rapid peer review
- Fast publication
- PubMed indexing
- Inclusion in Cases Database

Any patient, any case, can teach us something



**CASES
NETWORK**

www.casesnetwork.com